Congenital Pulmonary Diseases

Dr. Ahmed Saleh

PROF. Bassam Darwish

Congenital Pulmonary Diseases

- disorders of the trachea
- bronchial branching abnormalities
- bronchopulmonary foregut malformations (BPFMs),
- lung bud anomalies
- vascular abnormalities

HISTORICAL PERSPECTIVES

- **cystic pulmonary lesion** was first reported by Fontanus in **1639**.
- In **1777** Huber described an infant with an **intralobar sequestration** with blood supply from the thoracic aorta.
- Almost a **century later**, an **extralobar (Rokitansky lobe) sequestration** was reported.
- The **first surgical correction** of a congenital lung anomaly, a **lung cyst excision** in a 3-year-old boy, was performed by Rienhoff in **1933**

EMBRYOLOGY

- Lung development begins prenatally and continues into adulthood.
- The former is divided into four phases:
  - embryonic (1 to 5 weeks)
  - pseudoglandular (5 to 16 weeks)
  - canalicular (16 to 26 weeks)
  - terminal sac (26 weeks to birth).

EMBRYOLOGY
embryonic phase

- **foregut** begins to develop from the embryonic endoderm on **day 9**
- the **median pharyngeal groove** develops from the foregut on **day 22**
- At approximately 4 weeks of gestation, the **respiratory diverticulum**, or lung bud, emerges as a **3-mm out pouching** from the ventral wall of the embryonic foregut , surrounded by **splanchnic mesenchyme → visceral pleura**.

EMBRYOLOGY
embryonic phase

- Concurrently, the **lateral mesoderm** grows to form the **tracheoesophageal septum**
- The **lung bud** initially forms the **trachea**
- **two bronchial buds** that enlarge to form the **right and left main bronchi** by the start of the **fifth week**.
- The individual five lobes become evident during the next few weeks

EMBRYOLOGY
pseudoglandular stage

- the **bronchial tree** develops, including the cuboidal and columnar **epithelial** layers and **cartilaginous rings**.
- airways and pulmonary arterial branches remain **separated** by mesenchyme
- By the **16th week**, the **bronchial tree** and the pulmonary **arteries** are **fully formed**, and the common pulmonary vein drains into the sinoatrial region of the heart

EMBRYOLOGY
canalicular phase

- respiratory bronchioles divide to form alveolar ducts.
- Additionally, the **mesenchyme** separating the airways from the pulmonary arterial branches begins to **recede**, allowing the first appearance of the **air-blood barrier**.
- By the **25th week**, the pulmonary **venous** drainage has **completely developed**.

EMBRYOLOGY
terminal sac period

- The **adult form** of alveoli develops by **weeks 30 to 36**
- Type II pneumocytes **produce surfactant**
- postnatally : **alveolar multiplication** that results from progressive septation within the **terminal sacs**
- Acinar development continues till the 8th year of life(300 million acini), but the rate of development diminishes after ages 2 to 4 years.
- After the **10th** year of life, alveoli **enlarge** (The lung-environment interface increases from 3 to 4 m2 at birth to 75 m2 in adults.)

EMBRYOLOGY

- lung function returns to normal within 9 to 12 months of infant pneumonectomy
- From birth till the 5th year of life, airway diameter increases. After this, the proximal airway grows at a faster rate than the more distal airways.
- The trachea is initially funnel-like, but becomes more cylindrical by the age of 4 years

TRACHEAL AGENESIS AND ATRESIA

- fewer than 200 cases reported
- **incompatible with life** in the absence of a tracheoesophageal or bronchoesophageal connection.
- **Male** incidence predominates in a **2:1 ratio**.
- **90%** : other congenital lesions, including VACTERL , complex congenital heart defects, upper extremity defects, and duodenal atresia
- **respiratory distress, the inability to cry, and the inability to be intubated.**
- endo esophageally intubated+ nasogastric tube

Type I: The trachea originates from the esophagus, and the distal trachea, including the carina, is fairly normal This is present in 10% to 13% of patients with tracheal agenesis.

Type II: The trachea and carina are fused to the esophagus with no residual trachea. This deformity represents 59% to 62% of all cases.

Type III: The left and right mainstem bronchi originate from the esophagus, and there is no carina. This constitutes 22% to 31% of all cases

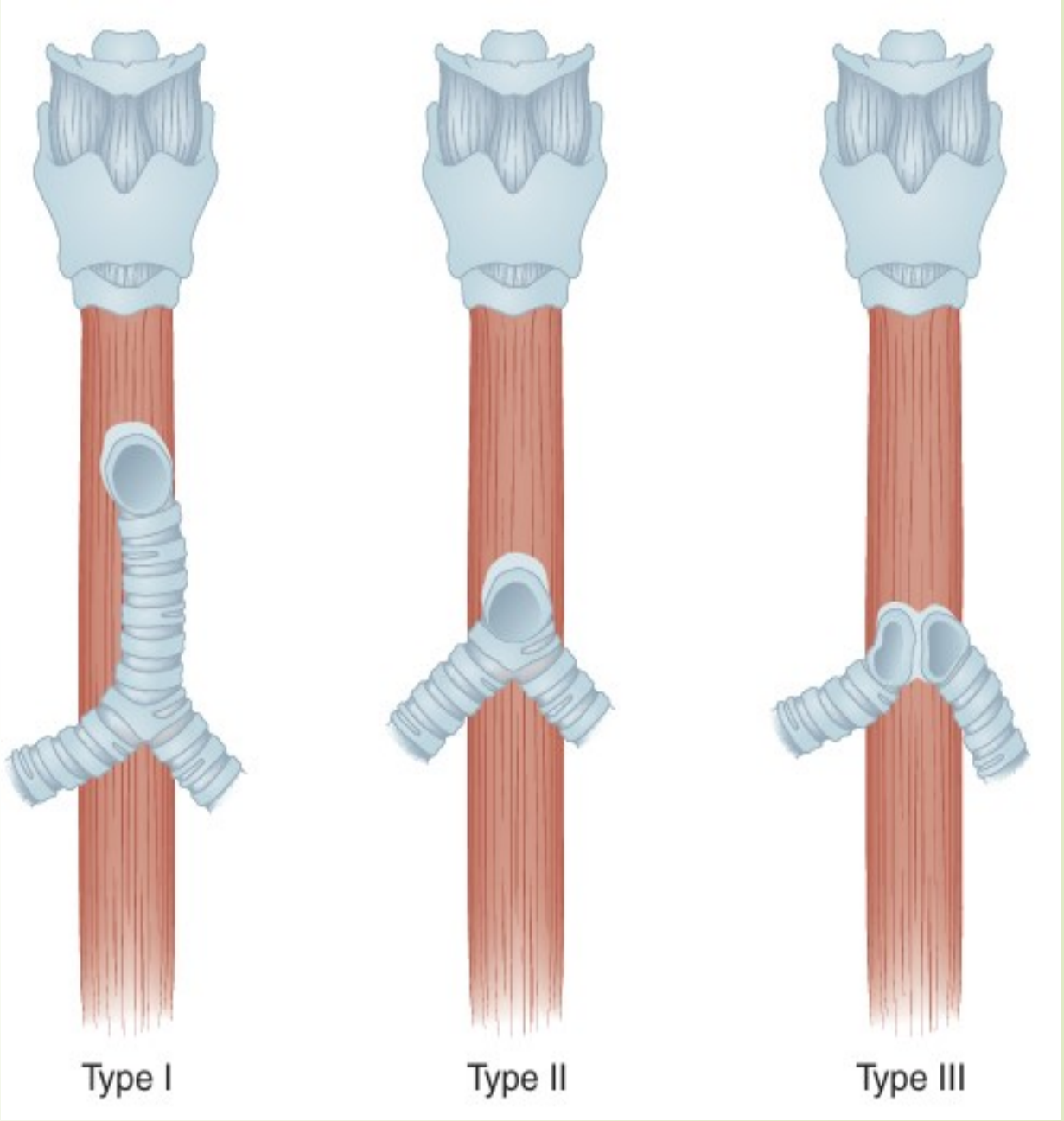

TRACHEAL AGENESIS AND ATRESIA

- Esophageal intubation, gastrostomy, and thoracic esophageal banding (type I and type II defects)
- "**neotrachealization**" of the esophagus with **external stenting** and fistulas left in situ.
- **gastric or jejunal interposition**
- esophagus can also be **divided longitudinally** to create a parallel neotrachea originating from the tracheoesophageal fistula and terminating as a **cervical stoma.**
- tracheal allograft and tissue-engineered replacements.

CONGENITAL TRACHEAL STENOSIS

- 1 in 64,500 cases
- complete tracheal rings, the posterior membranous trachea is absent
- the tracheal lumen diameters as small as 2 to 3 mm
- Tracheal involvement with such rings can be either short (<30% of the total tracheal length) or long segment
- Significant cardiovascular anomalies are often simultaneously present

CONGENITAL TRACHEAL STENOSIS

- **type I (generalized)**
- **type II (funnel-like)**
- **type III (segmental stenosis)**
- Type II and type III abnormalities are associated with anomalous location of one or more bronchi.
- children presenting at 1 year of age or soon thereafter have a surgical mortality of 10% to 20%.

CONGENITAL TRACHEAL STENOSIS

- **CT:** delineate the tracheobronchial abnormality, assessing any associated vascular anomalies
- **Bronchoscopy:** diagnosis, treatment planning, and evaluation of the surgical repair intraoperatively and postoperatively
- **Echocardiography:** cardiac abnormalities; tetralogy of Fallot, ventricular septal defect, complete atrioventricular canal, and double-outlet right ventricle

CONGENITAL TRACHEAL STENOSIS

- In **short-segment** tracheal stenosis, tracheal resection with primary anastomosis is the preferred method of tracheal reconstruction, with 1% to 8% mortality
- slide tracheoplasty is the operation of choice for **long-segment** tracheal stenosis , mortality ranges from 1% to 9%

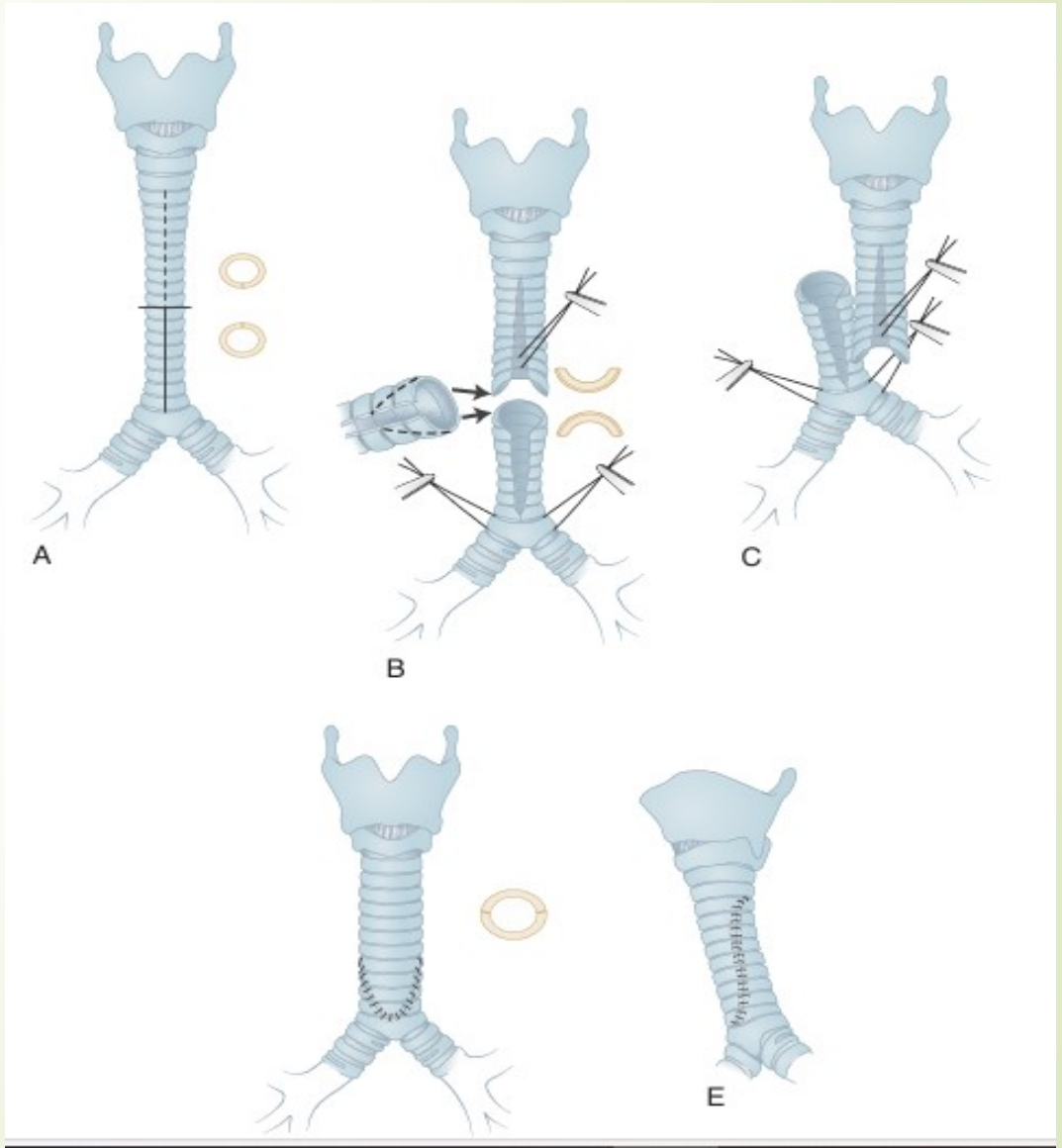

TRACHEOMALACIA

- The most common pathologic finding is **oval**, rather than **round** cartilaginous rings.
- **congenital** and **acquired**
- **diffuse**, involving both the proximal and distal trachea, along with the mainstem bronchi, and is generally associated with tracheoesophageal fistula
- The more common, **acquired** form results from degeneration of the cartilaginous support, compression from a vascular ring, an adjacent inflammatory process, tumor compression, or a chest wall deformity (e.g., pectus excavatum)

TRACHEOMALACIA

- Tracheomalacia does not normally manifest at birth (usually after several weeks of life).
- Coughing, respiratory distress, severe dyspnea, stridor, ,cyanosis can occur. Acute apnea "dying spells".
- **bronchoscopy** **gold standard** for diagnosis
- important adjuncts include CT, tracheoscopy, esophagoscopy, and esophagography
- Tracheomalacia improves with age in most cases.

TRACHEOMALACIA

- Dying spells, inability to be weaned from the ventilator, and failure to thrive are **indications** for more aggressive therapy.
- mortality rate **80%** with conservative management.
- **Stents:** to allow cartilage maturation.
- **Tracheostomy**
- **mild** tracheomalacia: supporting and observation, infants usually outgrow their tracheomalacia within 2 years of diagnosis.

TRACHEOMALACIA

- **Aortopexy**, with or without tracheal resection or stenting,
- After exposure of the ascending aorta, three or four nonabsorbable sutures and attached to the periosteum
- endotracheal result is visualized by intraoperative bronchoscopy
- 4 weeks: 80% of patients are extubated, 10% to 15% failure rates

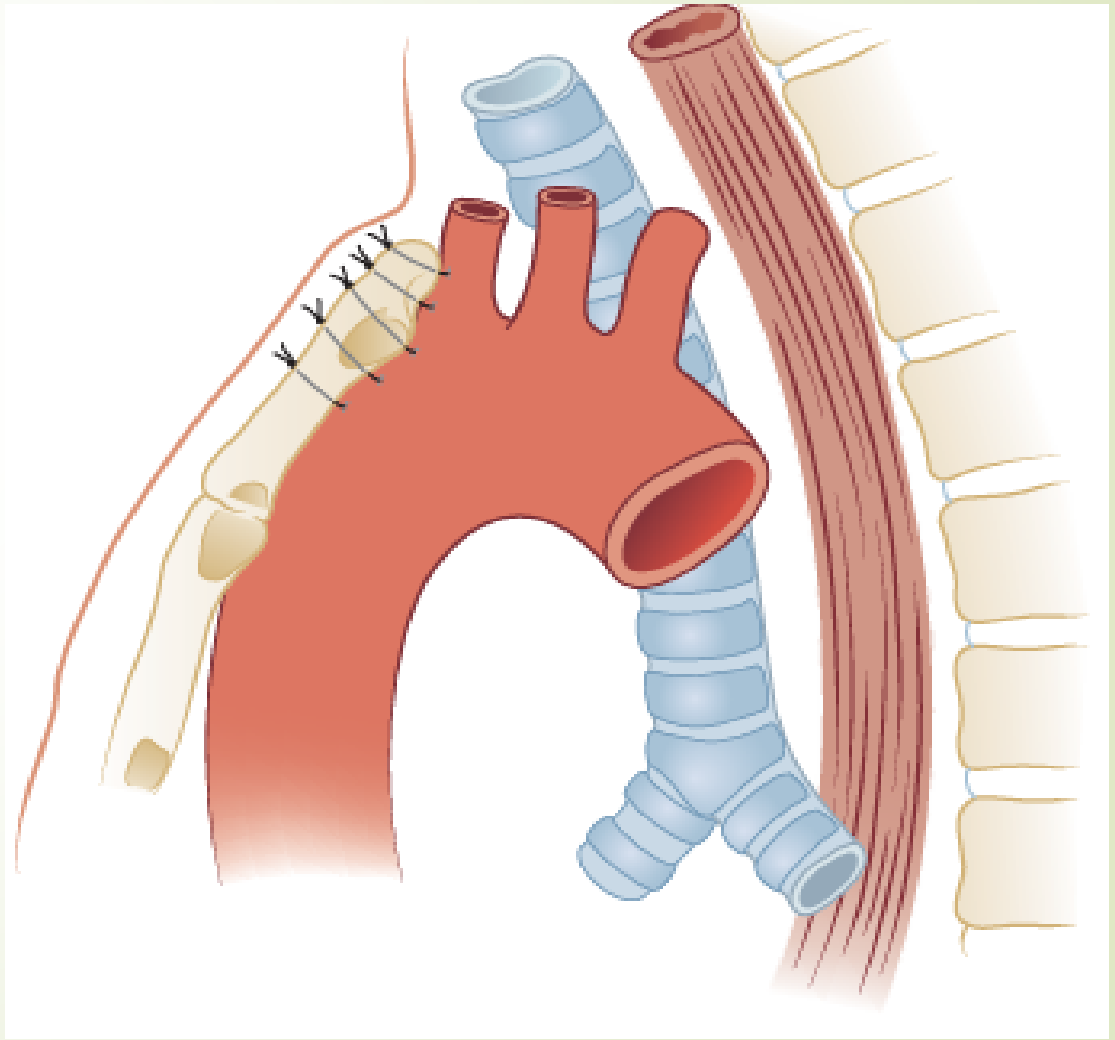

Thanks for listening