Congenital Pulmonary Diseases
part 2:bronchial branching abnormalities

محاضرة رقم ٢
١٩١-١٨٩
Sabiston and Spencer Surgery of the chest _10th edition

Dr. Bilal Othman
PROF. Bassam Darwish

Congenital Pulmonary Diseases

- disorders of the trachea
- **bronchial branching abnormalities**
- bronchopulmonary foregut malformations (BPFMs),
- lung bud anomalies
- vascular abnormalities

BRONCHIAL BRANCHING ABNORMALITIES

- 0.1% to 2%
- rarely symptomatic،
- wheezing, stridor, pneumonia, bronchiectasis, and hemoptysis
- originate off the trachea or mainstem bronchi.
- tracheal bronchus, or bronchus suis
- Chest radiography, high-resolution CT, fiberoptic bronchoscopy, bronchoalveolar lavage, and biopsy.
- If symptomatic :should be resected ,Contemporary methods endobronchial aspiration, lung resection, and transplantation


A

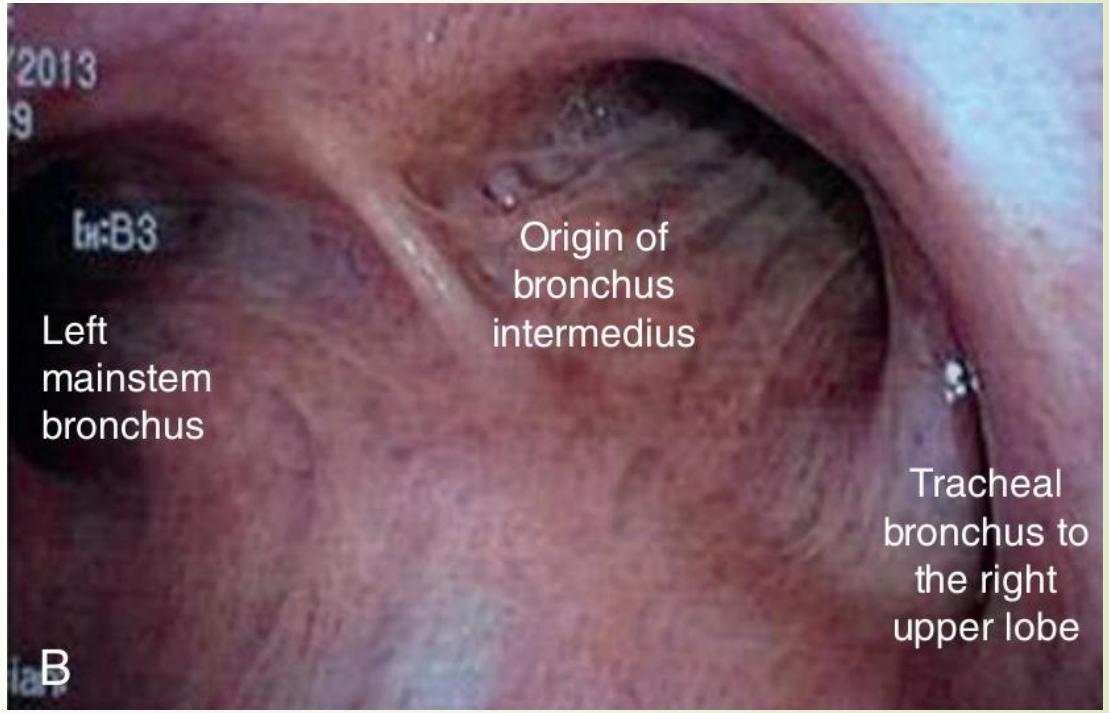
2013
Origin of bronchus intermedius
Left mainstem bronchus
Tracheal bronchus to the right upper lobe
B

BRONCHIAL ATRESIA

- First described by Ramsay and Byron in 1953,
- is the second most common abnormality of the airway after tracheoesophageal fistula.
- a lobar or segmental bronchus ends blindly in lung tissue
- Infants usually develop respiratory distress. Wheezing, stridor, and repeated pulmonary infections
- The most common location is in the left upper lobe, then the left lower lobe, followed by the right upper lobe.

BRONCHIAL ATRESIA

- A segmental bronchus, > lobar bronchus,
- often presents as a lung mass
- **Diagnosis :**

Ultrasonography

CT

- **DDx :**acquired bronchial stenosis ,bronchial adenoma, sequestration, mucoid impaction, vascular compression syndrome, Swyer-James syndrome, and atypical bronchogenic cyst.
- **Indications for resect :**pulmonary infections, respiratory distress, and increasing size of the translucent lung.
- Segmentectomy is possible, but lobectomy is usually required.

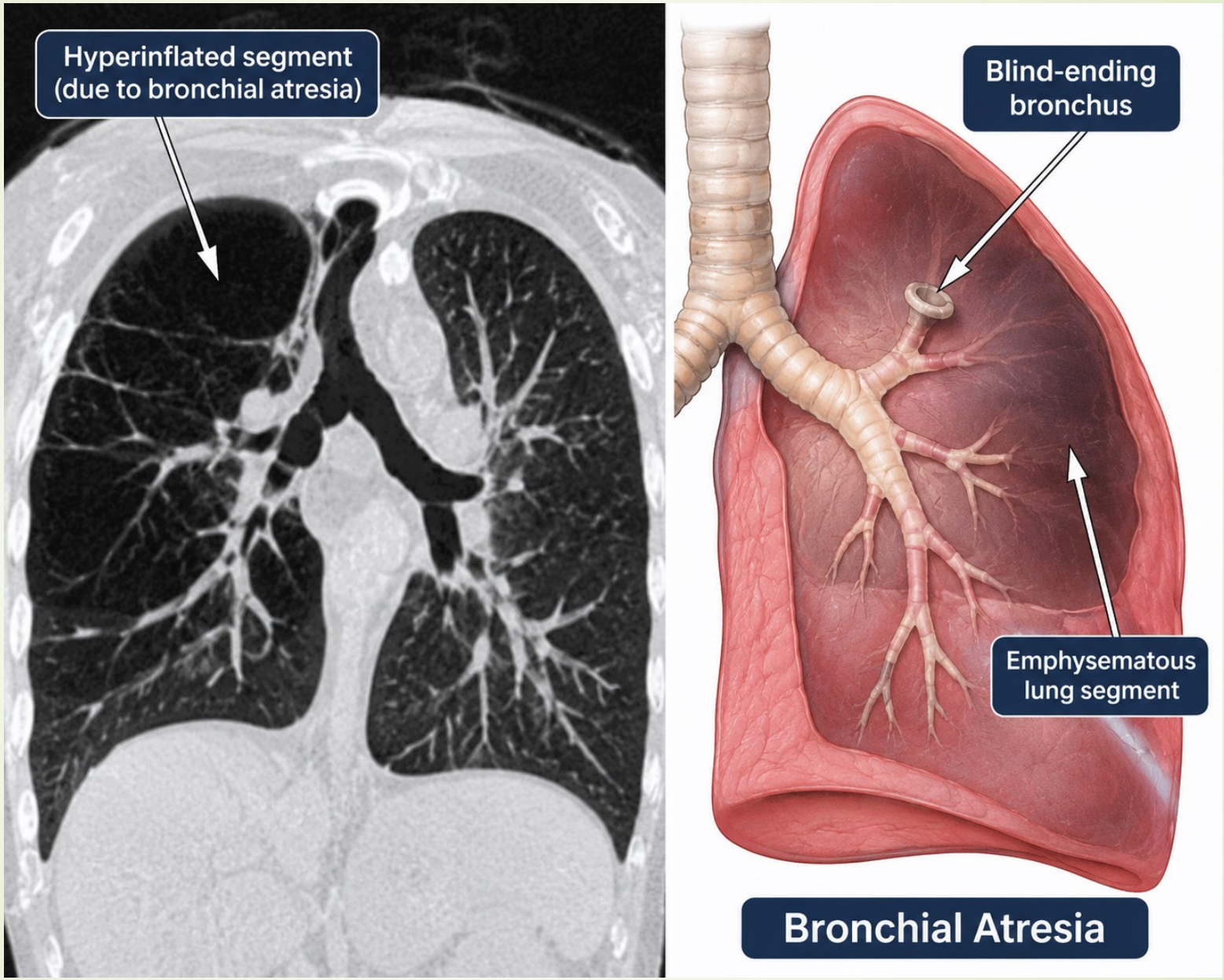
Hyperinflated segment
(due to bronchial atresia)
Blind-ending
bronchus
Emphysematous
lung segment
Bronchial Atresia

CONGENITAL BRONCHIECTASIS

- secondary to failure of mesenchymal tissue differentiation into cartilage and muscle.
- Cystic fibrosis, primary ciliary dyskinesia, Young syndrome, Williams-Campbell syndrome, a dna ,ycneicifed nispyrtitna-1 enummi yramirp niatrecdeficiency syndromes are associated with bronchiectasis
- present with a chronic, mildly productive ,cough with recurrent pneumonia
- CT
- bronchoscopy is generally unnecessary

CONGENITAL BRONCHIECTASIS

- **Treatment :**
- and prognosis depend on the number of segments or lobes
- humidity, chest physiotherapy, supplemental oxygen, and antibiotics as necessary
- Bronchoscopy : mucoid obstruction or bleeding
- localized congenital symptomatic bronchiectasis may require a segmentectomy, lobectomy, or possibly pneumonectomy

Congenital Bronchiectasis

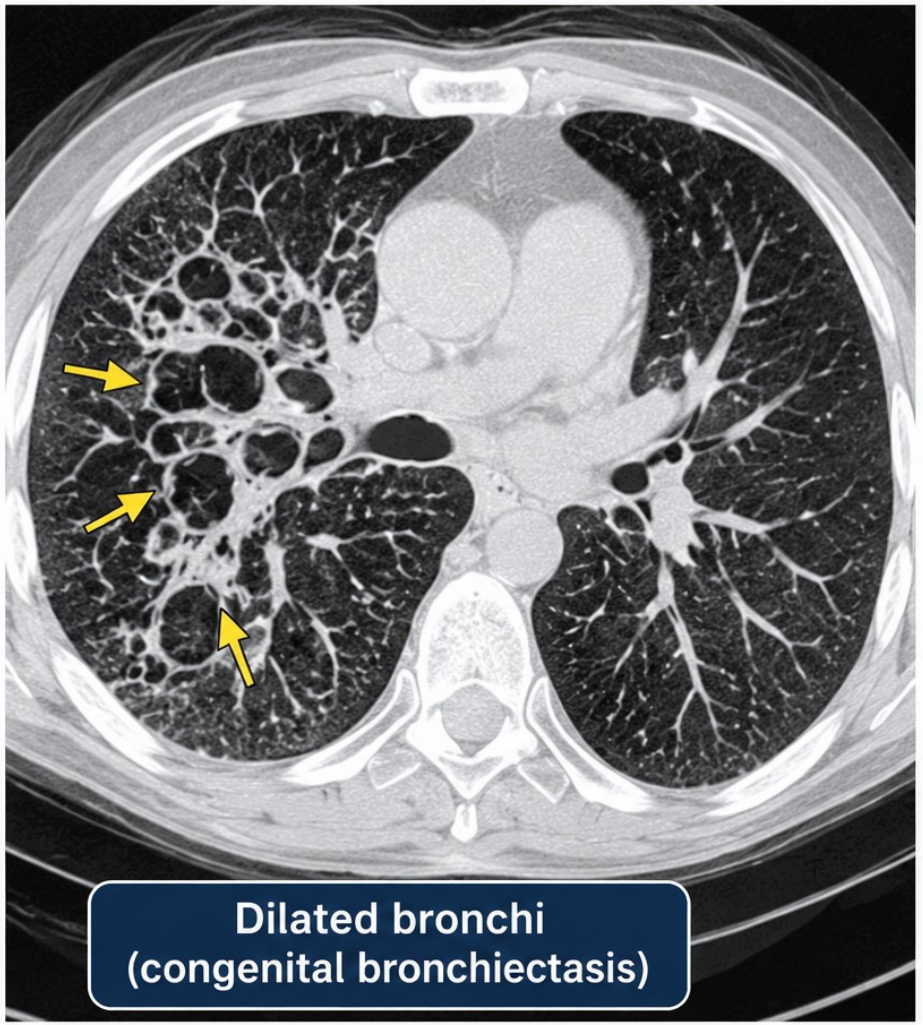

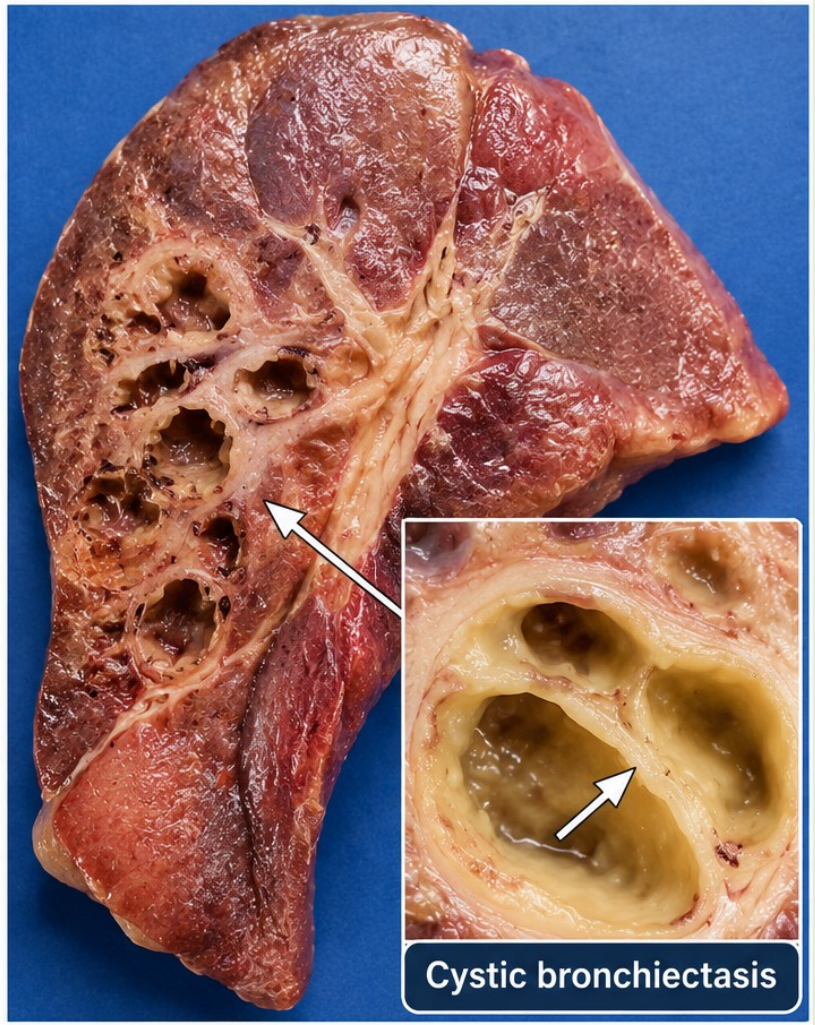

TRACHEOBRONCHOMEGALY (MOUNIER-KUHN SYNDROME)

- Firsst described by Mounier-Kuhn in ,1932
- characterized by excessive dilation of the tracheobronchial tree
- mucosal herniations develop between the tracheal rings, , creating a diverticulosis
- Associated conditions include cutis laxa, Ehlers-Danlos syndrome, Marfan syndrome, Kenny-Caffey syndrome, ataxia-telangiectasia, ankylosing spondylitis, Brachmann-de Lange syndrome, and light chain deposition disease.

MOUNIER-KUHN SYNDROME

- present in their third decade
- approximately >3cm in adults than normal.
  - CxR
  - Ct
  - Bronchography
  - Bronchoscopy
- Mangment :Silicone stents and T-tubes
- for membranous wall stabilization or tracheobronchoplasty.

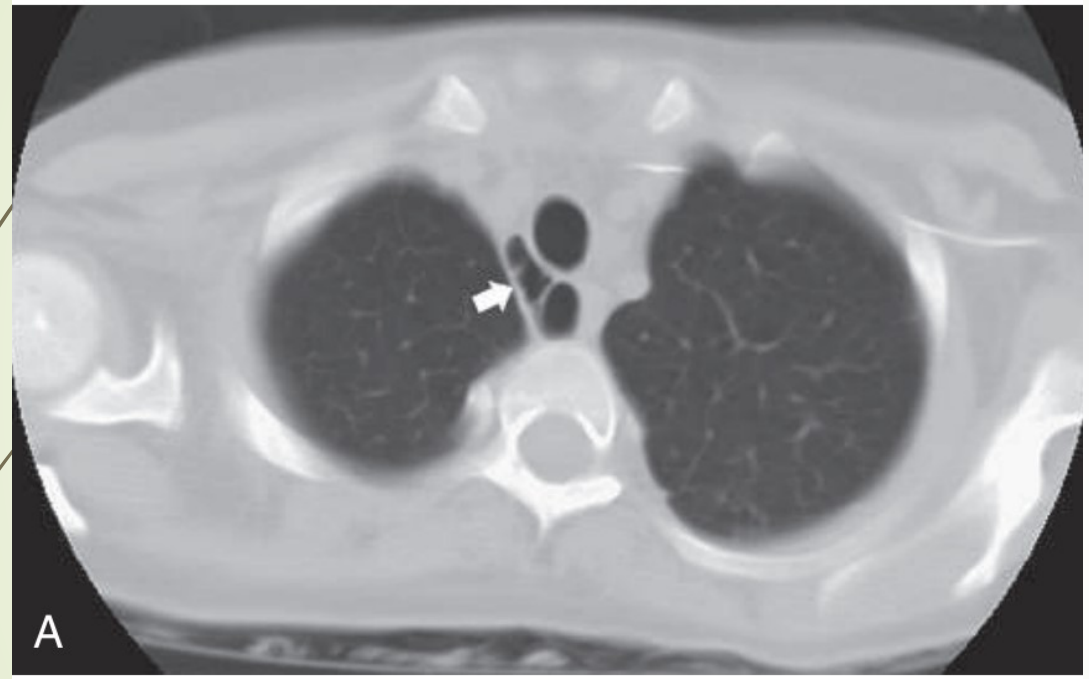
A

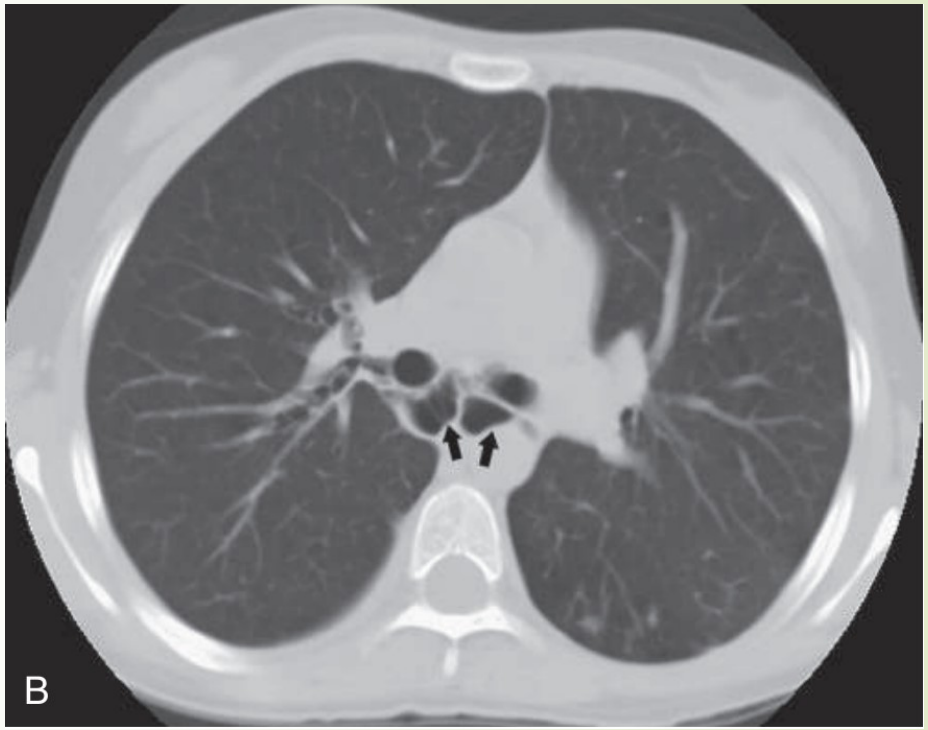
B

LARYNGOTRACHEOESOPHAGEAL CLEFT (LTEC)

- rare congenital abnormality resulting from failure of the esophagus to separate from the larynx and trachea.
- toneless cry and choke with feeding.
- barium study or endoscopy can demonstrate the fistula, **rigid bronchoscopy** is necessary
- Management: **length**
- Surgical repair, **:**require extracorporeal membrane oxygenation cardiopulmonary bypass,
- anterior approach,"
- "lateral approach,"
- cervicothoracic approach/, / endoscopic

Laryngotracheoesophageal Cleft (LTEC)

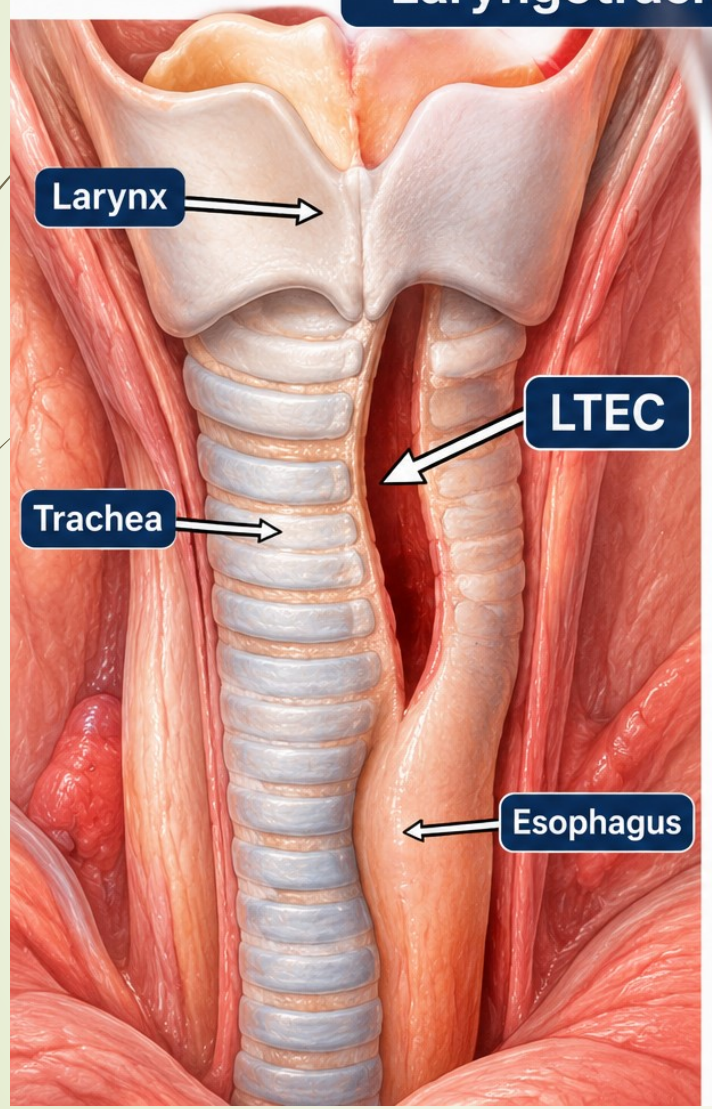

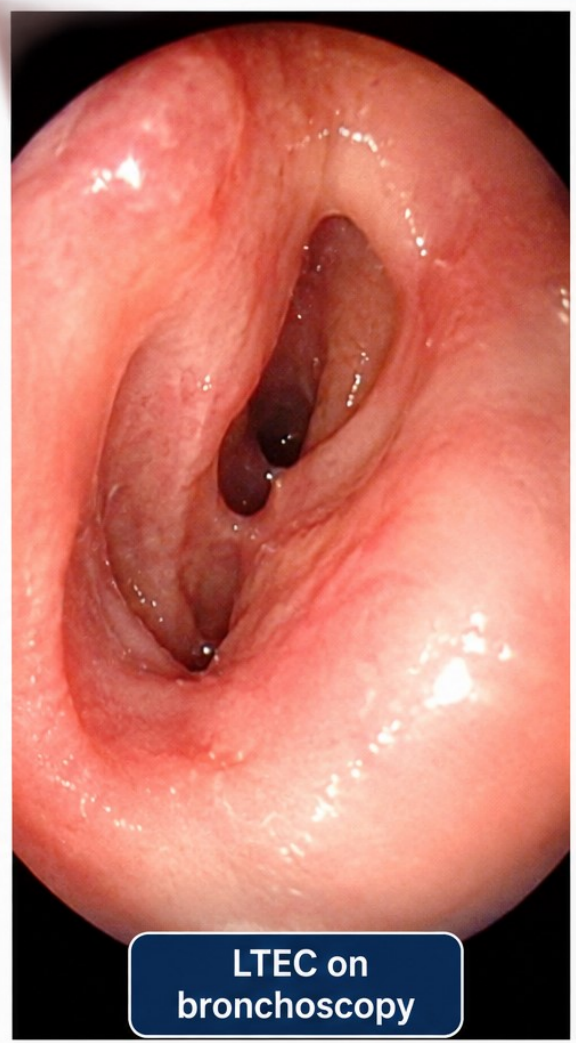

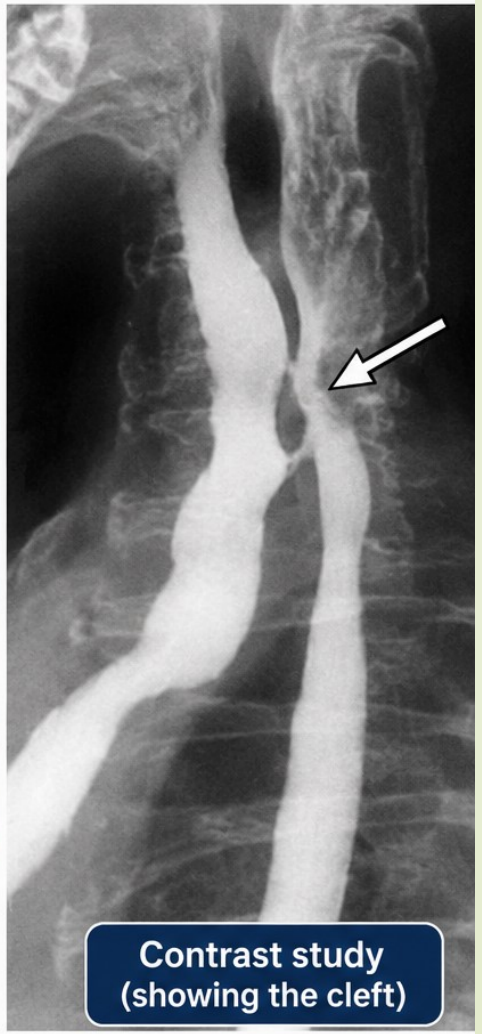

TRACHEOBRONCHIAL-ESOPHAGEAL FISTULA TEF

- the most common abnormality of the trachea,
- 2.4 out of 10,000 births.
- Gross classification:
  - type A, esophageal atresia without TEF; **%8**
  - type B, esophageal atresia with proximal TEF;**%1**
  - type C, atresia with distal TEF;**%87**
  - type D, atresia with both proximal and distal TEF; **%1**
  - type E, TEF without esophageal atresia (H-type)**%4** .
- cardiovascular anomalies **%35**
- 1/5 VACTERL(Vertebral-anal atresia-cardiac-TE-Renal-Limb)

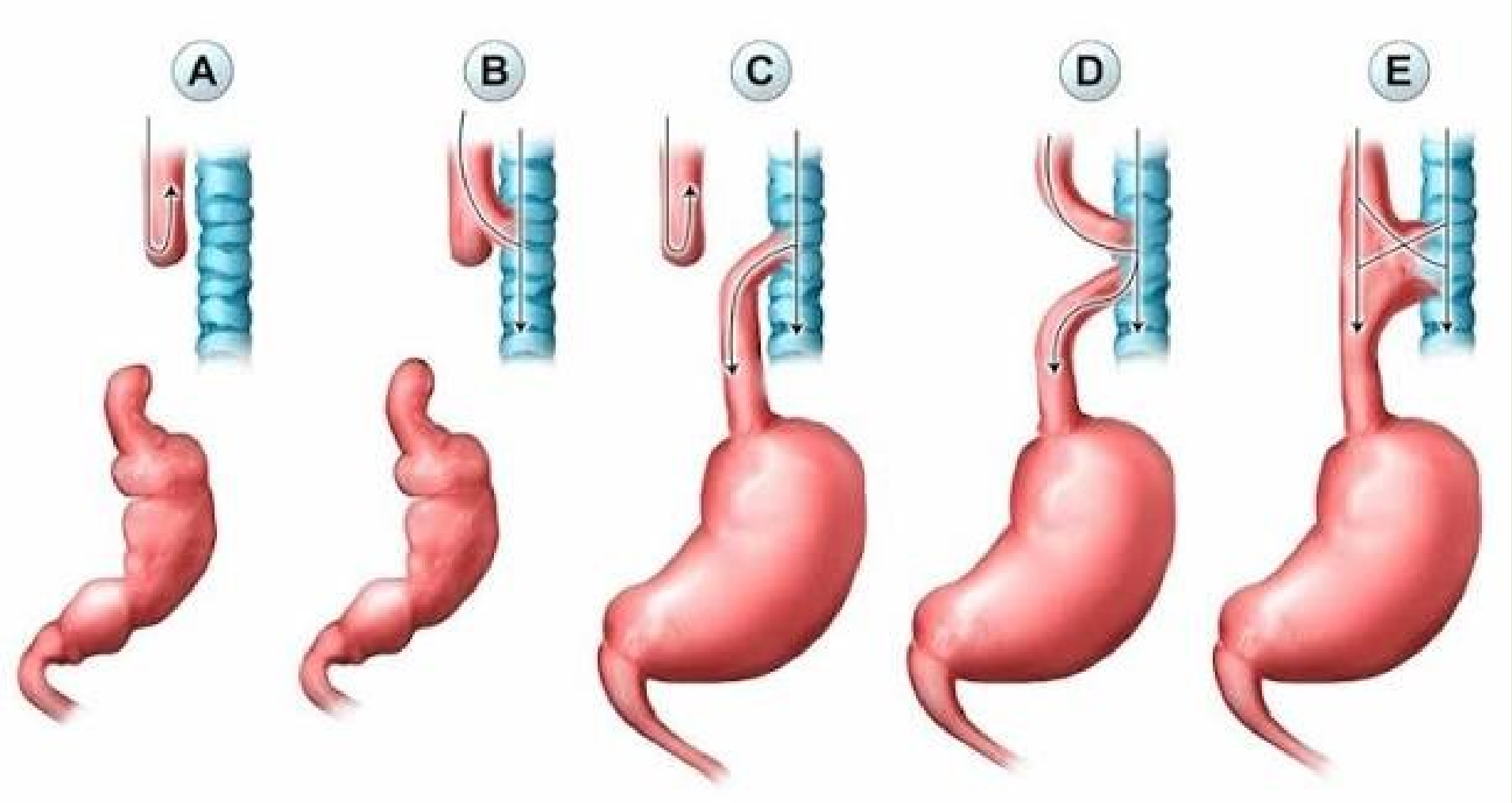
A
B
C
D
E

TEF

- Patients usually present with feeding difficulties and excessive salivation.
- Intermittent cyanosis and tracheobronchial infections
- Type C TEF is suspected :when a large amount of air is visualized in the esophagus, stomach, and small bowel
- Failure of nasogastric tube: radiography or contrast fluoroscopy

TEF

- Haight is credited with the first successful pediatric TEF repair
- left thoracotomy, Haight came to prefer right extrapleural thoracotomy
- Postoperatively, esophageal anastomotic leak is seen in approximately 15% of cases, but, with a functioning chest tube in proximity, 95% of leaks heal spontaneously
- Subsequent stricture formation is common, but generally responds well to dilation
- Major life-threatening leaks occasionally occur.
- esophageal replacement by colonic interposition or gastric transposition may be necessary

TEF

- H-type fistula:
- a right neck incision is made to avoid the thoracic duct. The sternocleidomastoid muscle and carotid sheath are retracted laterally. The recurrent laryngeal nerve is identified and protected, and the fistula is divided and oversewn. An interposition muscle flap reduces the likelihood of recurrence.

TEF

- In a recent survey of 217 surgeons from 31 countries, the thoracoscopic approach to repair was preferred by more than 50% of surgeons
- Compared with the open approach,
- thoracoscopic repairs are associated with similar mortality,
- equivalent rates of anastomotic leak and stenosis
- improved cosmesis,
- longer operative times,
- shorter postoperative ventilation times and hospital stays,
- and better ability to spare the azygos vein.

BRONCHOBILIARY FISTULA

- between the respiratory system and biliary tract
- Embryologically :represent a duplication of the upper gastrointestinal tract for the distance of the gut between the laryngotracheal outgrowth and the hepatic diverticulum
- fistulous tract, which is composed of bronchial and biliary-type
- Symptombs : green sputum and develop dyspnea and chronic cough
- .respiratory distress in infants

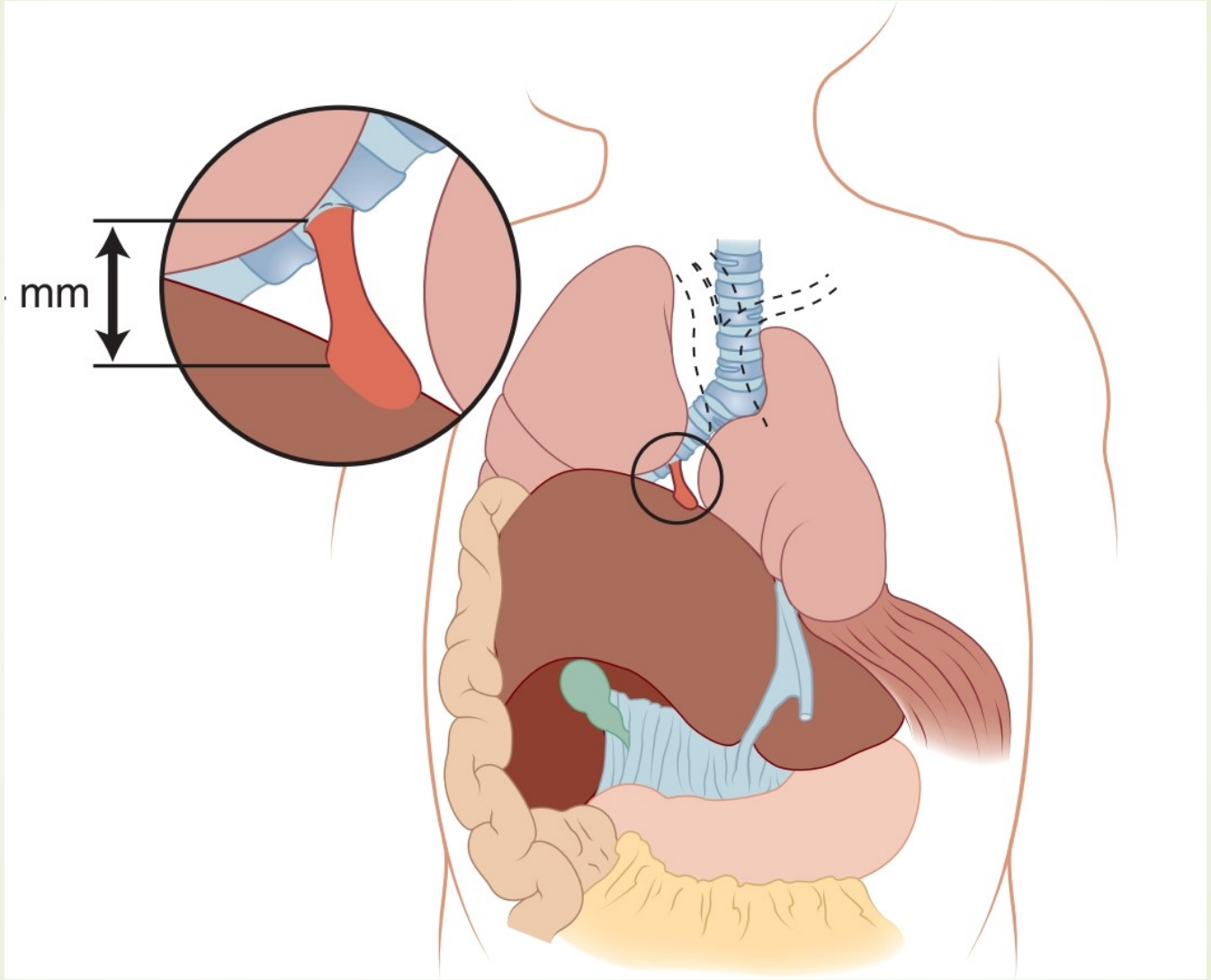
mm

BRONCHOBILIARY FISTULA

- The right middle lobe and right mainstem airways drain to the left hepatic ductal system
- Associated anomalies include esophageal atresia and TEF, biliary atresia, and right-sided diaphragmatic hernia.
- Diagnosis : bronchoscopy,nuclear biliary scan (99mTc-HIDAcholescintigraphy(. MRI
- Treatment:ligation and division of the fistula via transpleural or extrapleural right thoracotomy
- Hepatic Lobectomy (generally left-sided) or Roux-en-Y hepaticojejunostomy may be necessary.

Thanks for listening