Smoking-Related Interstitial Lung Disease

Eyad Almasri, MD

Professor of Clinical Medicine

University of California San Francisco

October2026

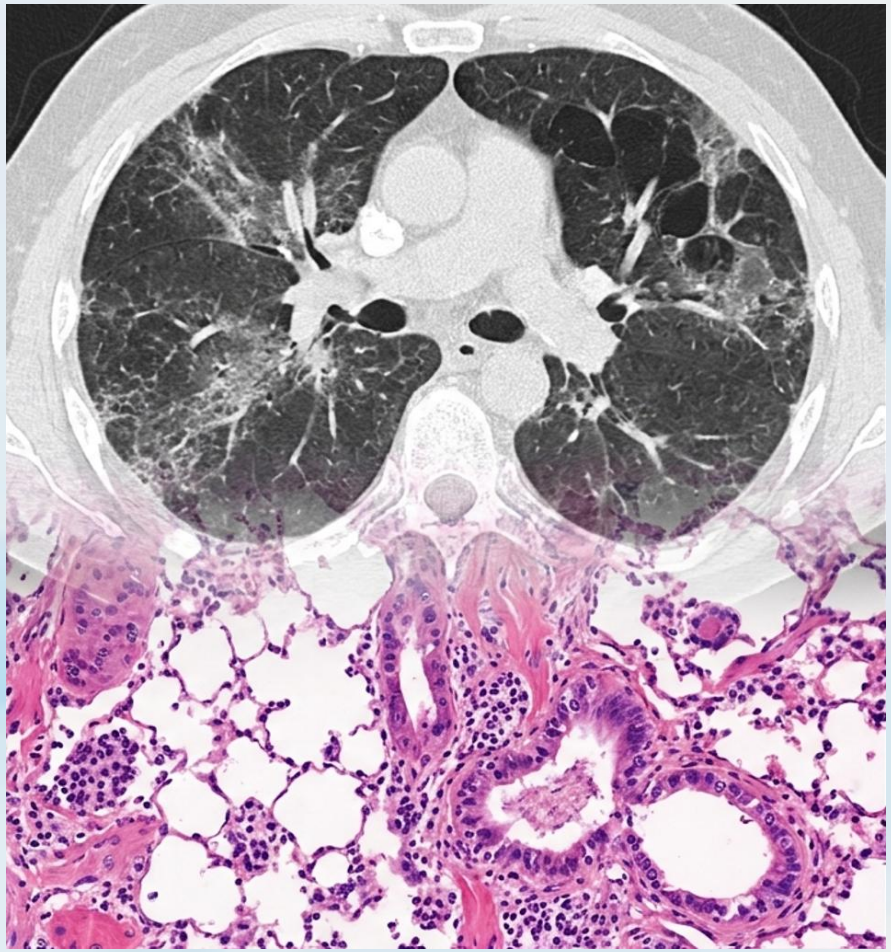

UCSF Fresno

Disclosures

- No financial conflict of interests
- I may have more Slides than I will be able to go over
- AI was used to demonstrate and enhance display not to generate a new content

- Defining the spectrum of smoking-related interstitial lung disease
- Macrophage-predominant disease: RB/RB-ILD and DIP/AMP
- Nodular-to-cystic disease: pulmonary Langerhans cell histiocytosis
- Fibrotic phenotypes: SRIF and combined pulmonary fibrosis and emphysema
- Acute inhalational injury: acute eosinophilic pneumonia and EVALI
- Diagnostic synthesis and the multidisciplinary approach

Learning Objectives

By the end of this talk, you will be able to:

- Recognize the major smoking-related interstitial lung disease phenotypes and their clinical context.
- Differentiate RB/RB-ILD, DIP/AMP, PLCH, SRIF, CPFE, AEP, and EVALI using characteristic CT and pathologic patterns.
- Integrate smoking history, imaging, pathology, and physiology to narrow the differential diagnosis.
- Identify when smoking cessation, targeted testing, biopsy, and multidisciplinary ILD review are most useful.

What Makes ILD "Smoking-Related"?

- Happens mostly in active or recent smoker(s)
- Tends to get better with quitting smoking

- Will go over major smoking-related ILD categories:
  - Macrophage response: mild/reversible
  - Structural fibrotic response
  - Acute exudative response

The Spectrum of Inhalation Injury

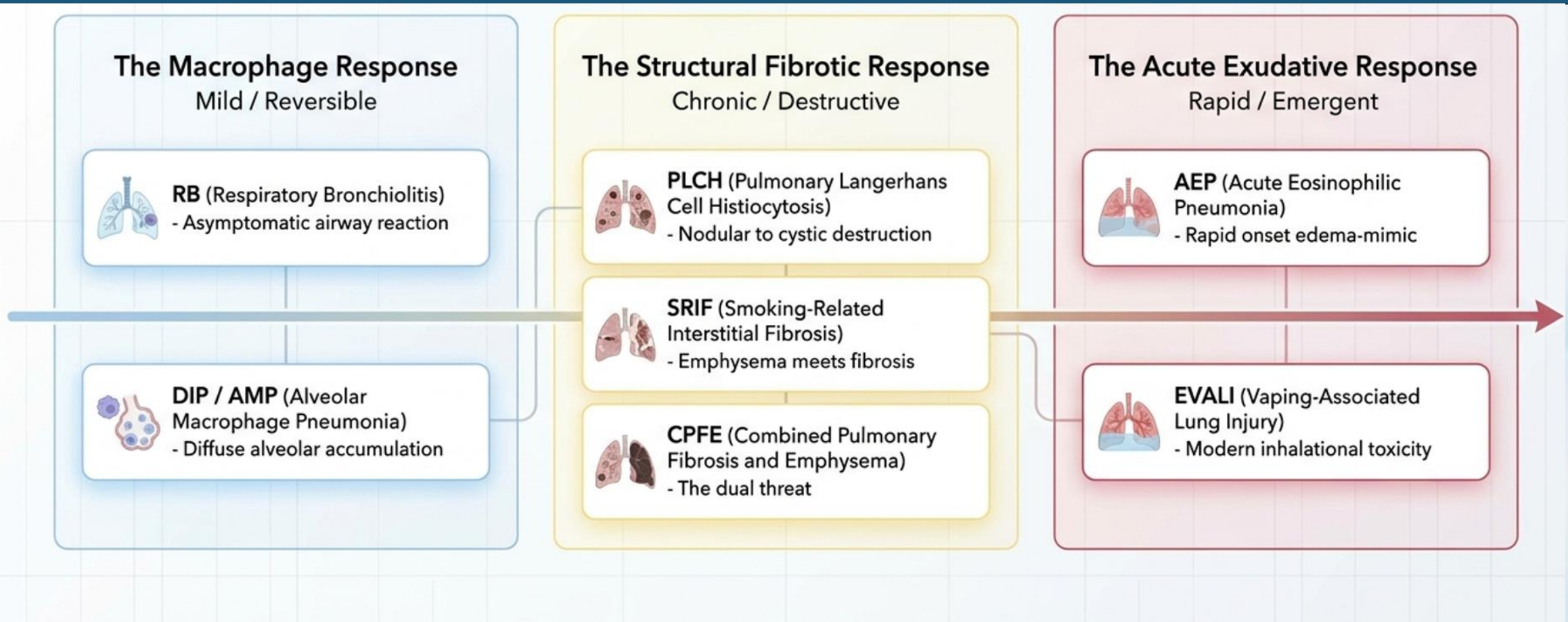

UCSF Fresno

Respiratory Bronchiolitis (RB) Represents the foundational macrophage tissue reaction to smoking

- 4th -5th decade
- Asymptomatic (normal PFTs)
- If symptomatic with impaired PFTS, clinically termed RB-ILD
- Treatment: strict smoking cessation

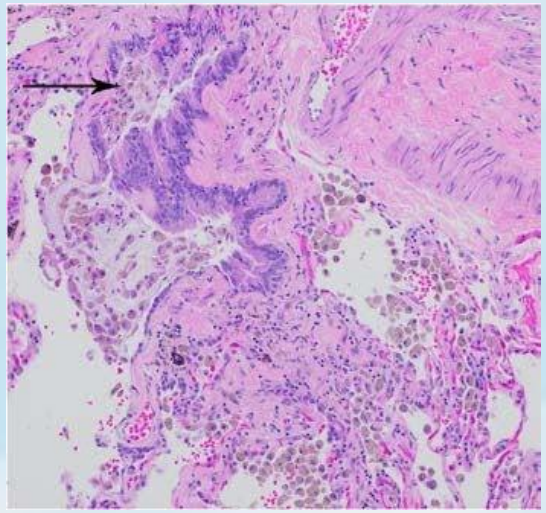

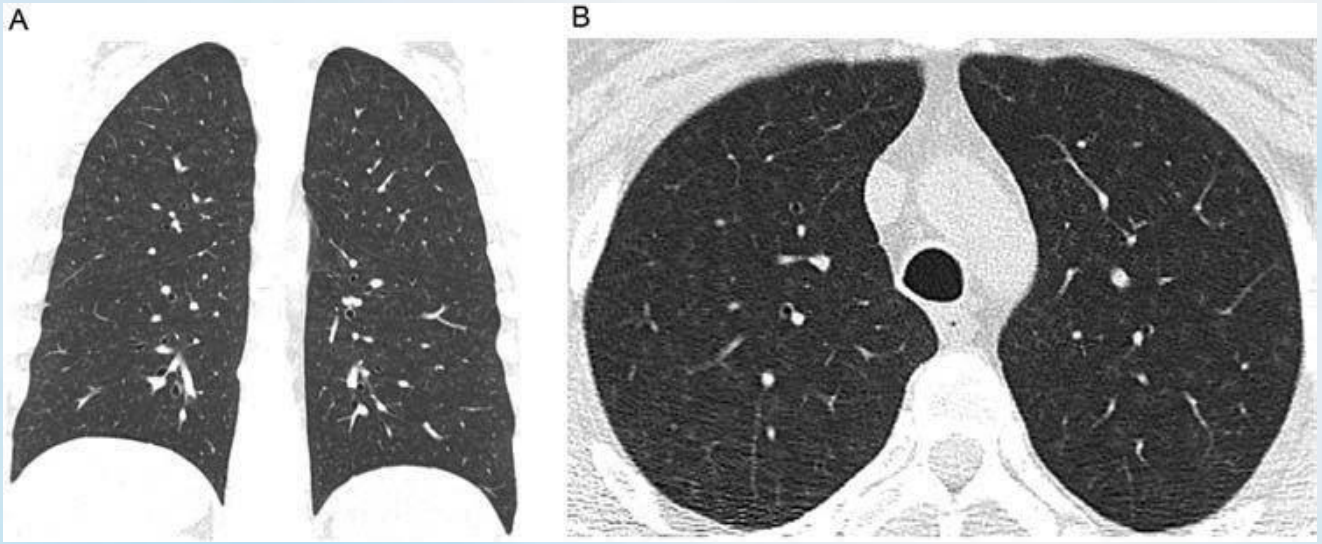

UCSF Fresno

The Spectrum of Inhalation Injury

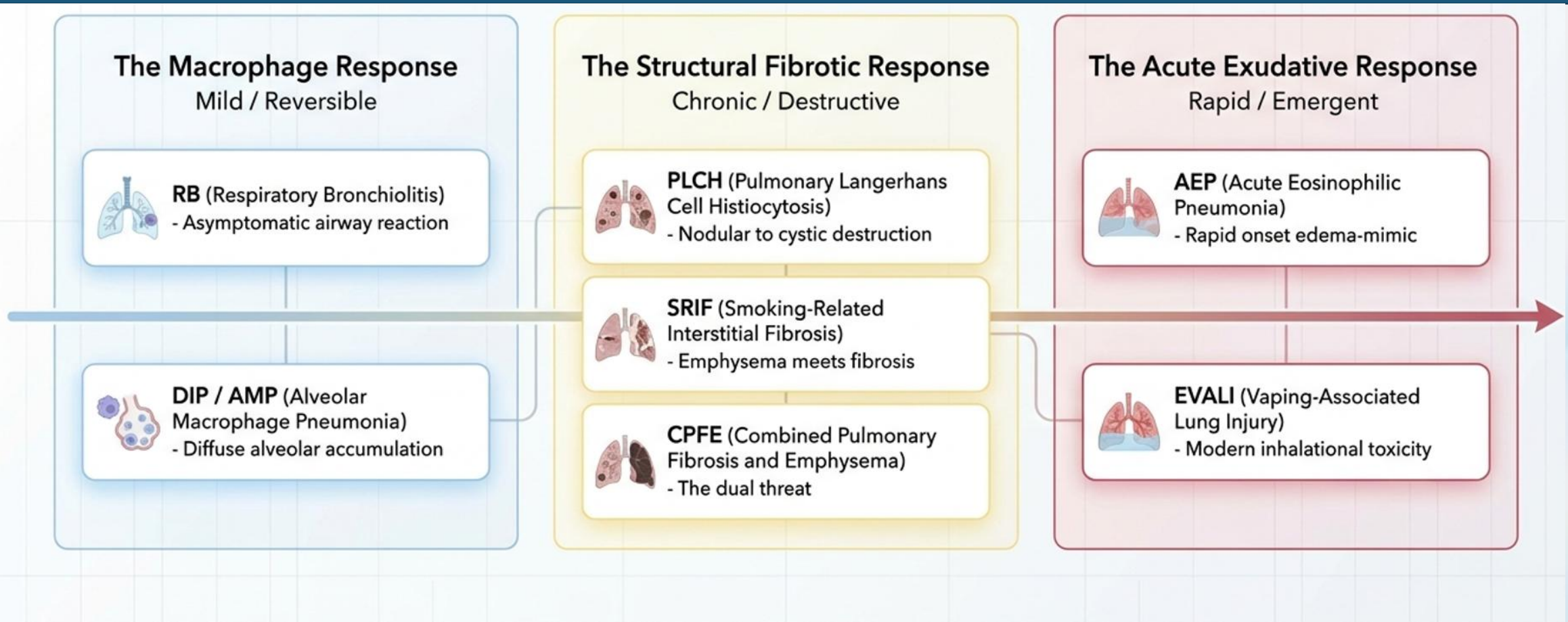

UCSF Fresno

DIP/AMP Shifts the Macrophage Accumulation from Patchy Airway to Diffuse Alveolar Space

- Symptomatic (dyspnea/ cough
- 50% show digital clubbing(chronic hypoxemia)
- PFTs show restrictive defect
- Note: "desquamative" is a historic misnomer, modern term is Alveolar Macrophage Pneumonia (AMP)

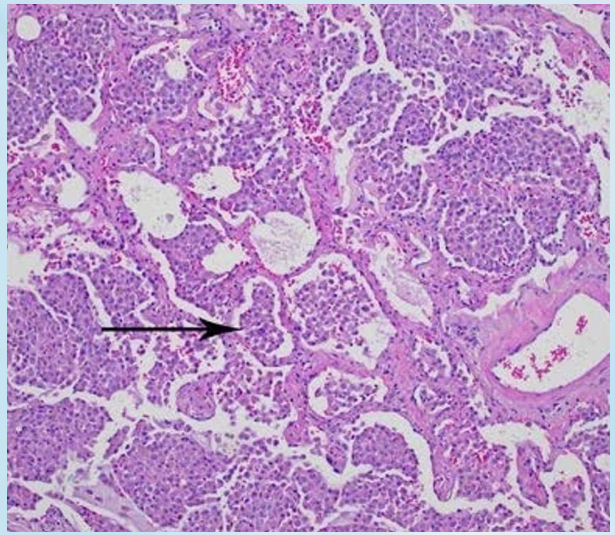

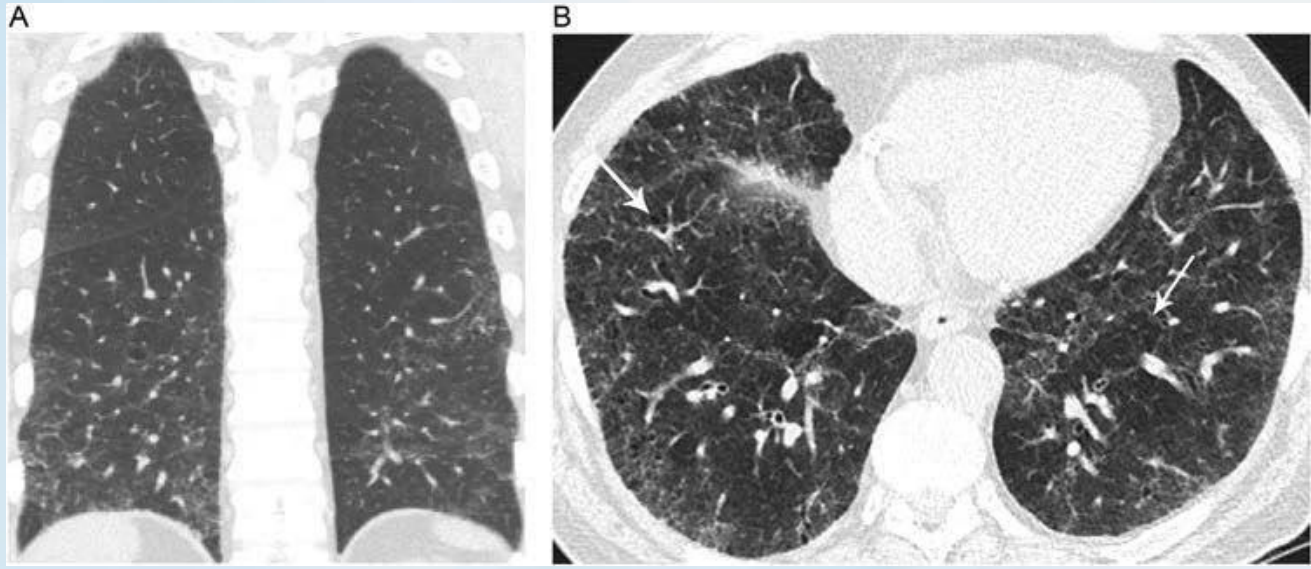

Lower lung predominant ground-glass opacity with associated small cystic spaces (indicating chronicity)

UCSF Fresno

The Spectrum of Inhalation Injury

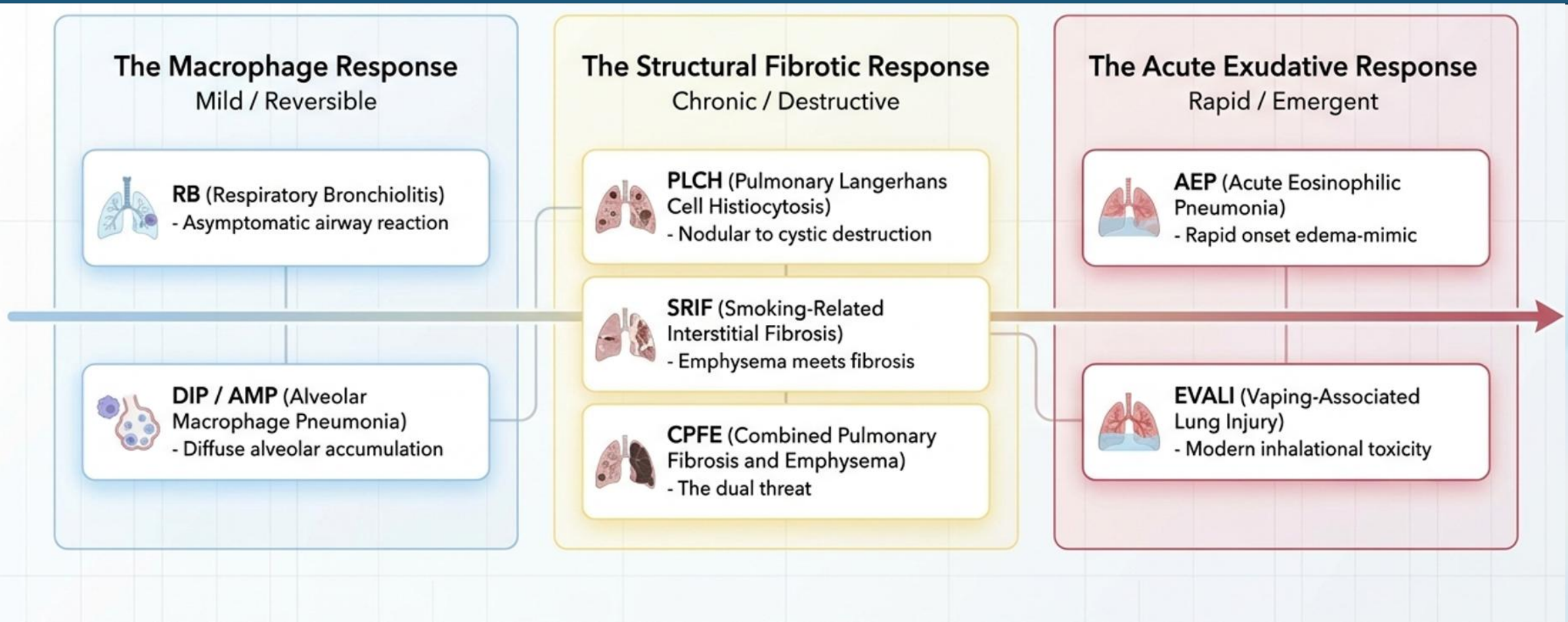

UCSF Fresno

Pulmonary Langerhans Cell Histiocytosis (PLCH) presents an insidious, nodular-to-cystic progression

- Almost exclusively in smokers
- 3rd-4th decade presentation
- Insidious onset: asymptomatic until exercise limitation
- Risk of spontaneous pneumothorax

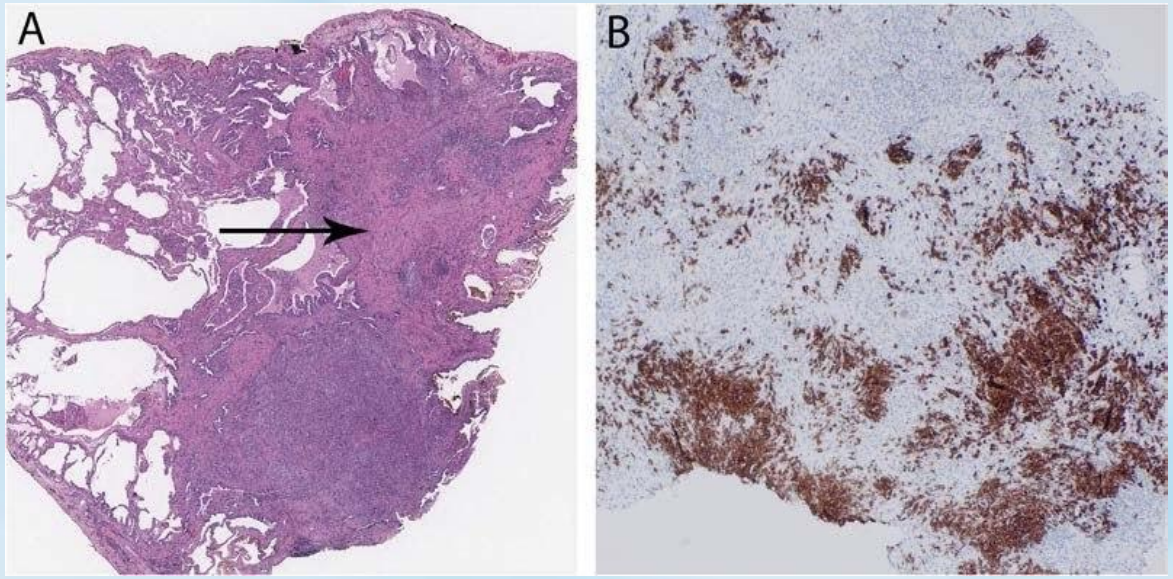

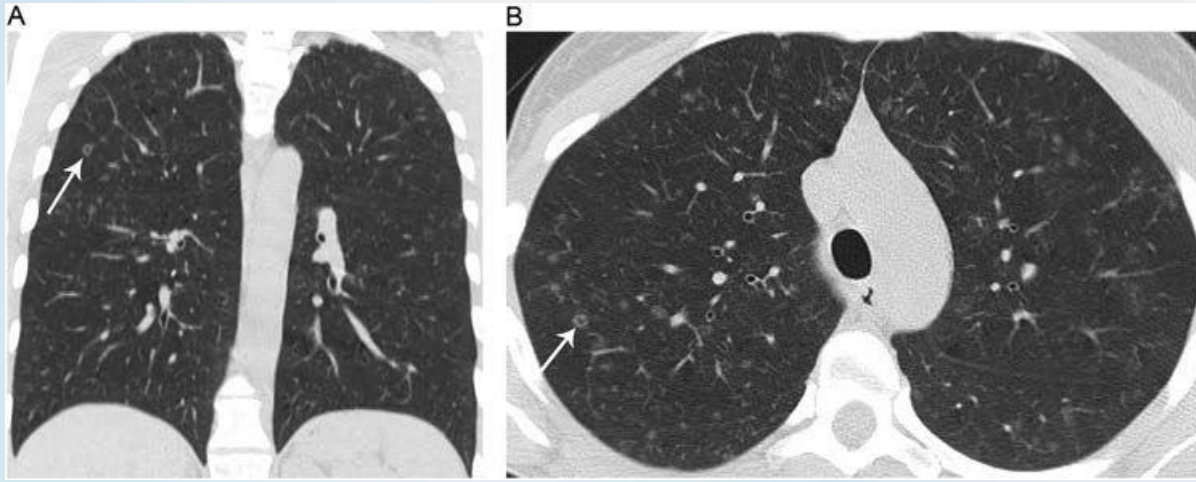

Centrilobular pulmonary nodules with mid/upper lung predominance
Sparing of the costophrenic angles

UCSF Fresno

The Radiological Lifecycle of PLCH: From solid nodules to bizarre cystic destruction.

1. Solid Nodule

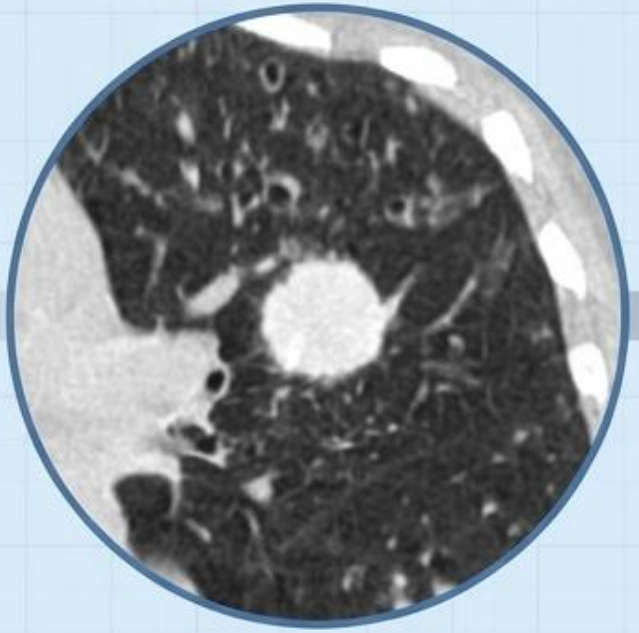

Initial centrilobular nodules form in mid/upper lungs.

2. The ‘Cheerio’ Cavitation

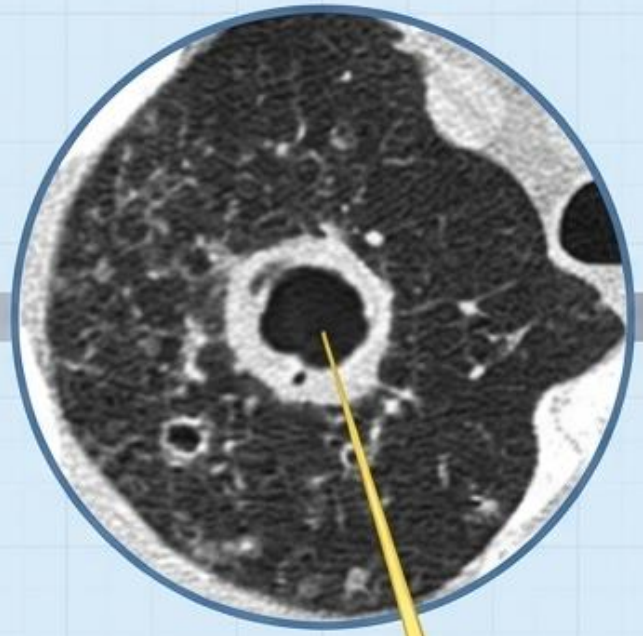

Central umbilication with a solid peripheral component creates the classic ‘cheerio’ appearance.

3. Bizarre End-Stage Cysts

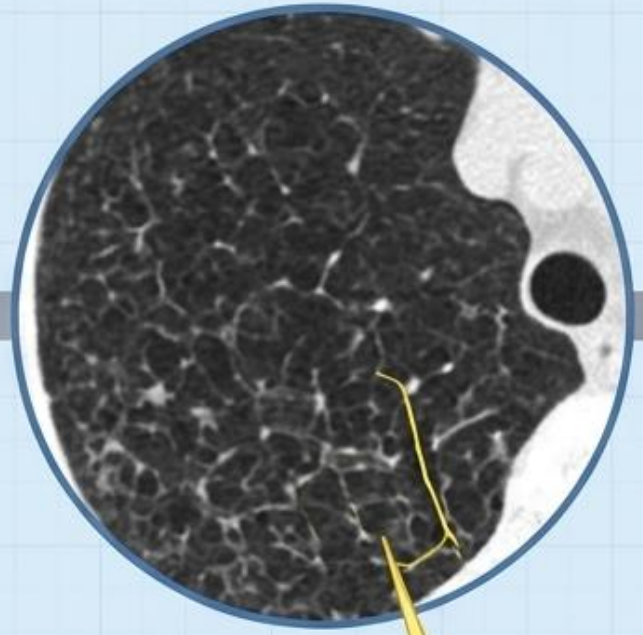

Complete loss of solid components results in irregular, bizarre cystic morphology. Distinguishable from emphysema by preserved vasculature and well-defined cyst walls.

Gemini Notebook


General Mills
Gluten Free
first ingredient
Whole Grain Oats
NATURALLY FLAVORED
Honey Nut
Cheerios
made with Real Honey
CAN HELP
LOWER CHOLESTEROL*
AS PART OF A HEART HEALTHY DIET
Sweetened Whole Grain Oat Cereal
with Real Honey & Natural Almond Flavor
NET WT 10.8 OZ (306g)



UCSF Fresno

The Spectrum of Inhalation Injury

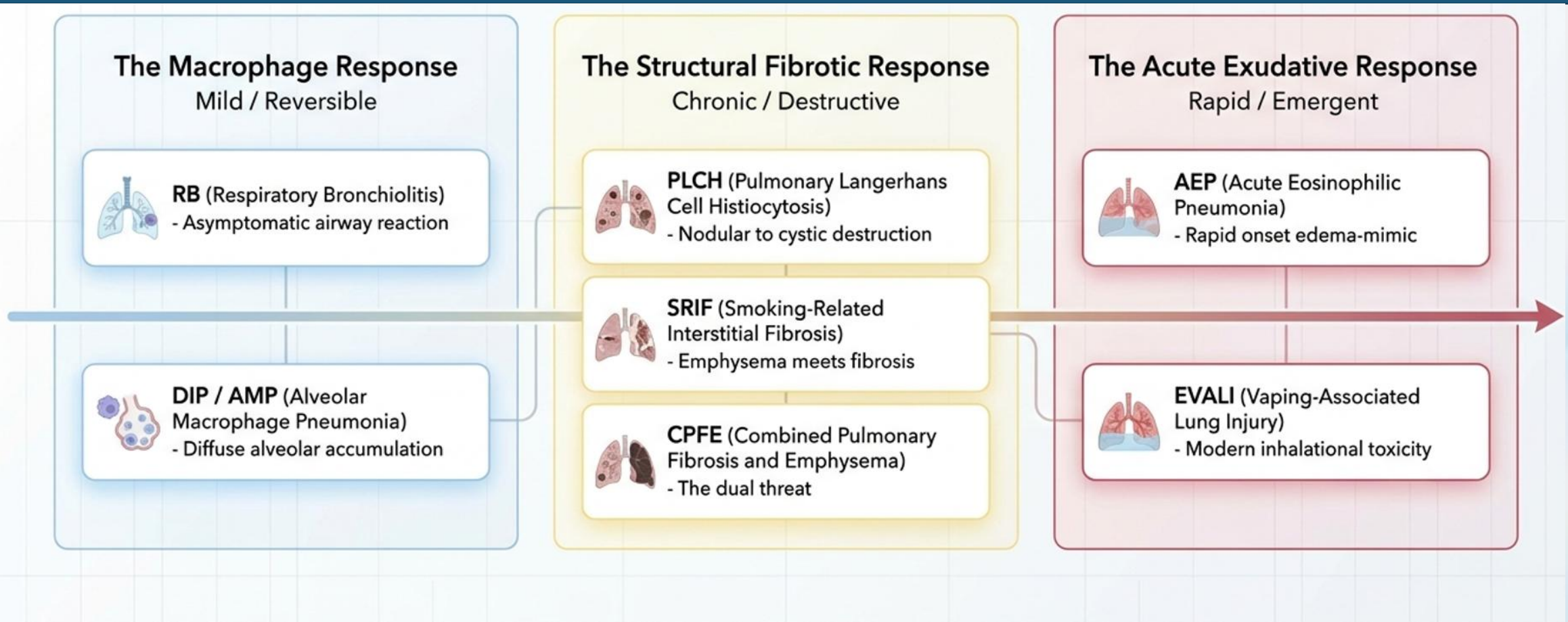

UCSF Fresno

Smoking-Related Interstitial Fibrosis (SRIF) Manifests as Dense Fibrosis Intertwined with Emphysema

- Median age 46, progressive dyspnea
- PFTs consistently show reduced DLCO
- Intervention: stabilize with smoking cessation
- Synonymous histologically with air space enlargement with fibrosis (AEF)

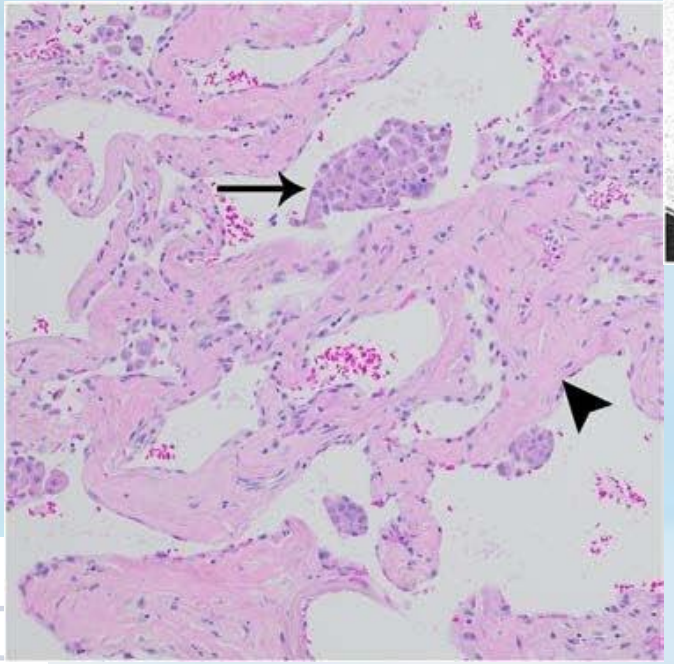

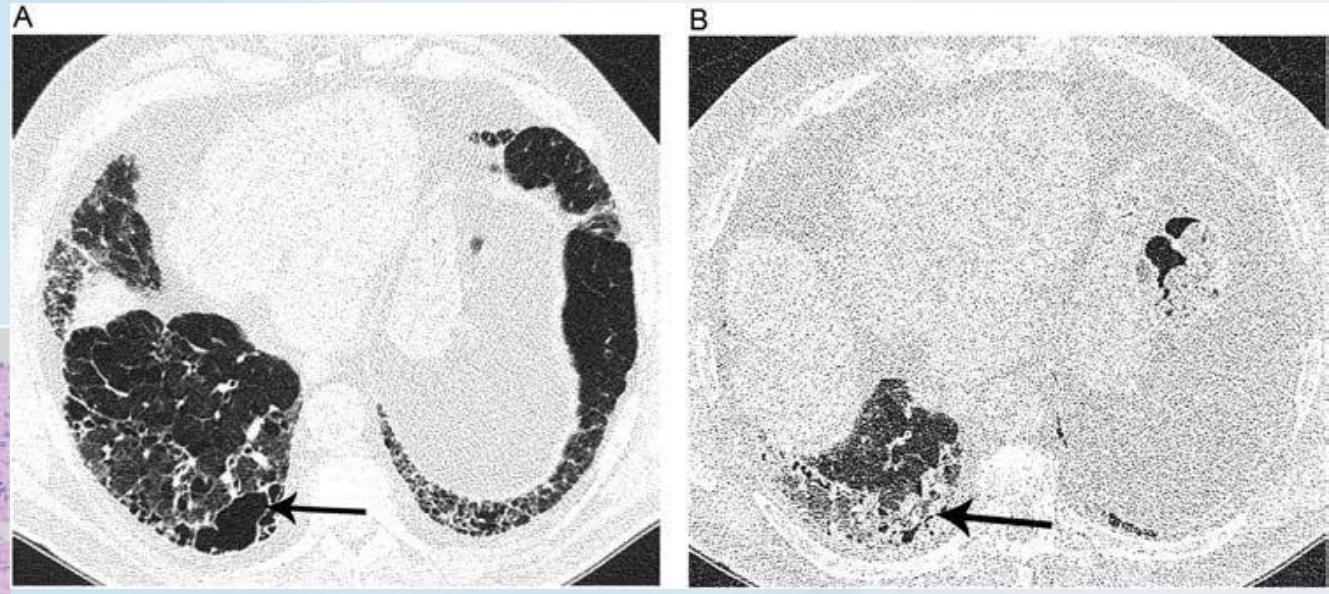

Well-defined, thick-walled subpleural cysts
Overlying fibrosis makes emphysematous space appears distinctly thick-walled

Diagnostic Differentiation: SRIF vs. True Honeycombing.

SRIF Cysts

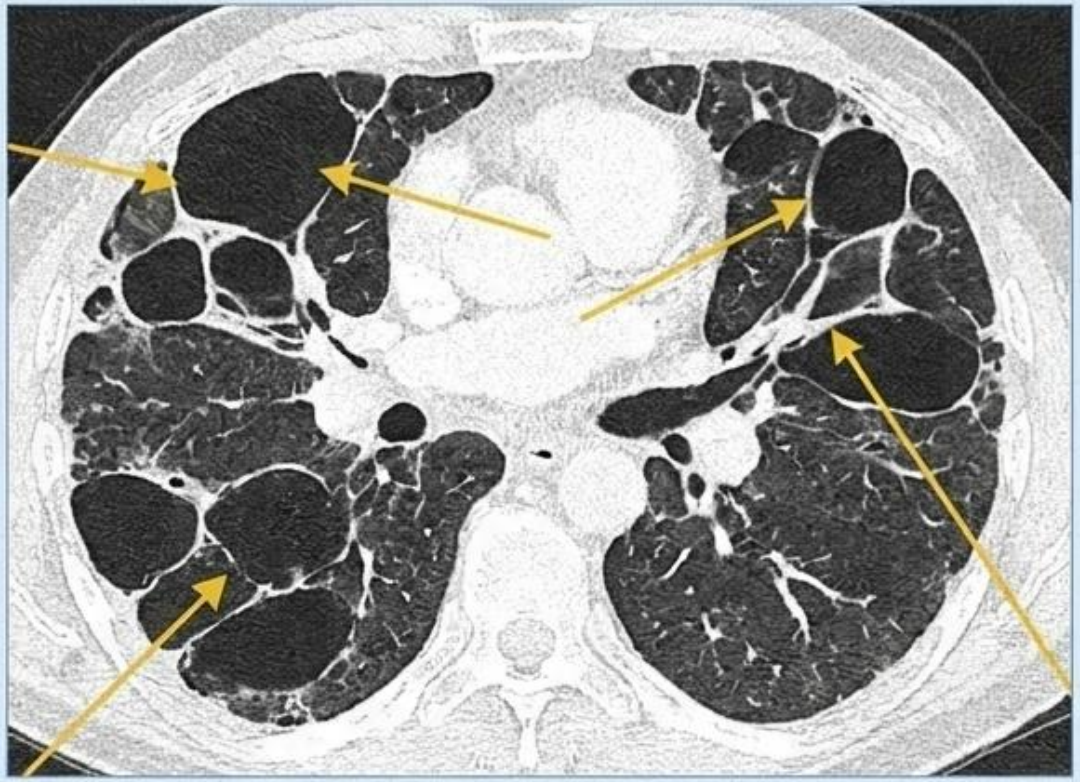

- Larger cystic spaces with partial septations
- Spares the inferior costophrenic angles
- **Key Differentiator:** Dynamic expiratory imaging reveals these cysts collapse upon expiration due to airway communication.

UIP Honeycombing

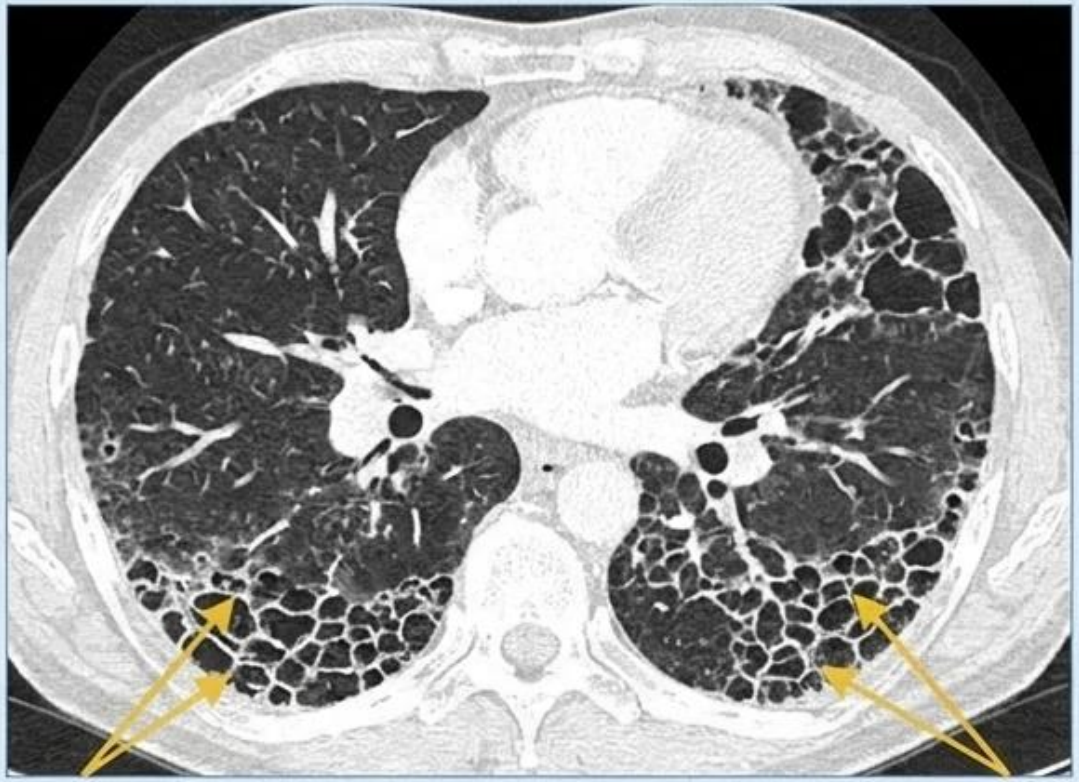

- Small, rigid, stacked cysts
- Primarily basal and subpleural distribution
- **Key Differentiator:** These cysts are rigid and do **NOT** collapse on expiratory phase imaging.

Gemini Notebook

Combined Pulmonary Fibrosis and Emphysema (CPFE) exhibits distinct upper and lower pathologies

- 6th-7th decade, strong male predominance
- Severe pulmonary hypertension is common
- High incidence of lung CA (42%)

Biopsy is rarely performed due to exacerbation risk. Diagnosis relies heavily on radiologic findings: identifying emphysema with a superimposed non-SRIF fibrotic pattern (usually UIP)

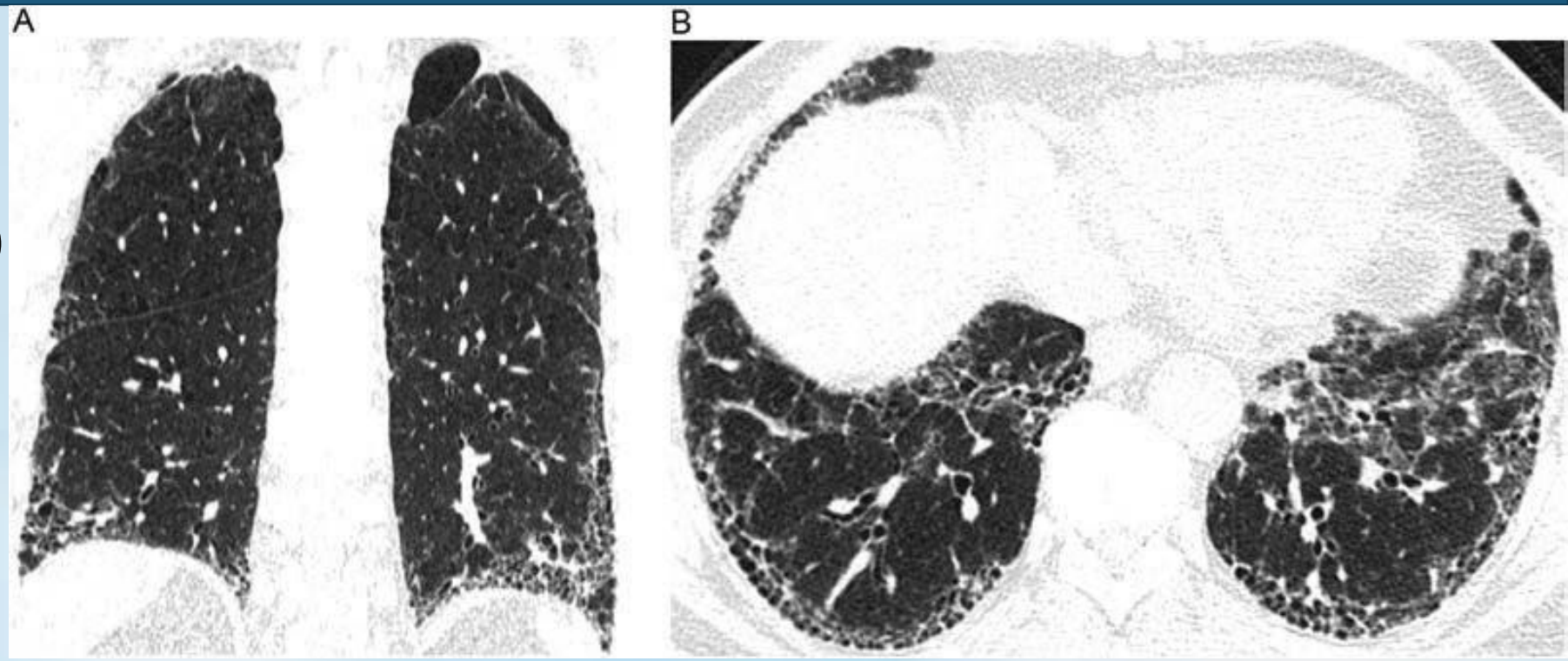

UCSF Fresno

The Spectrum of Inhalation Injury

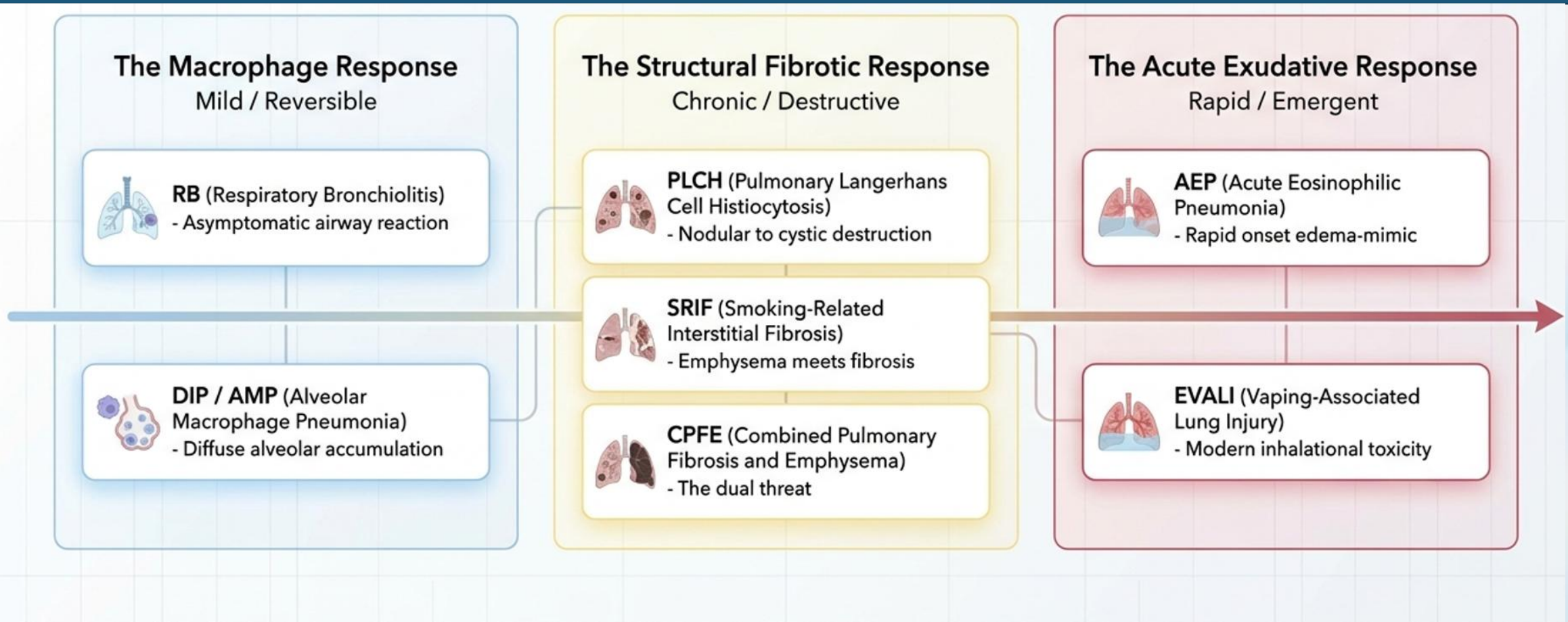

UCSF Fresno

Acute Eosinophilic Pneumonia (AEP) mimics cardiogenic edema but develops rapidly after altered smoking habits

- Acute onset (days) of cough, dyspnea and fever
- Young patients (3rd decade typical)
- Often coincides with new smoking onset or increased quantity
- Sever cases may require mechanical ventilation

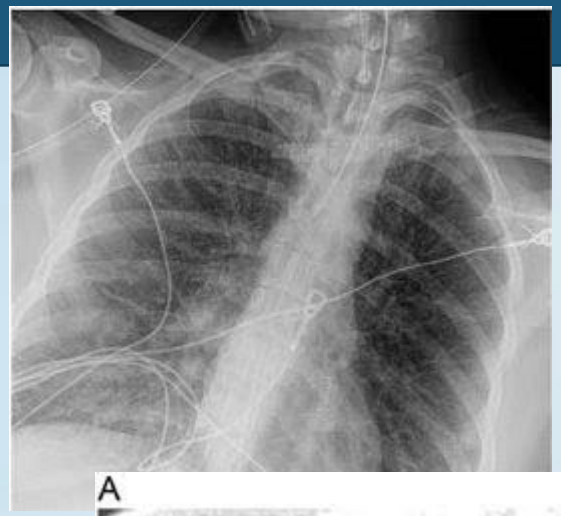

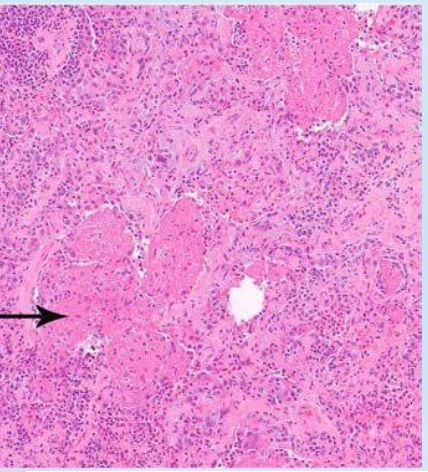

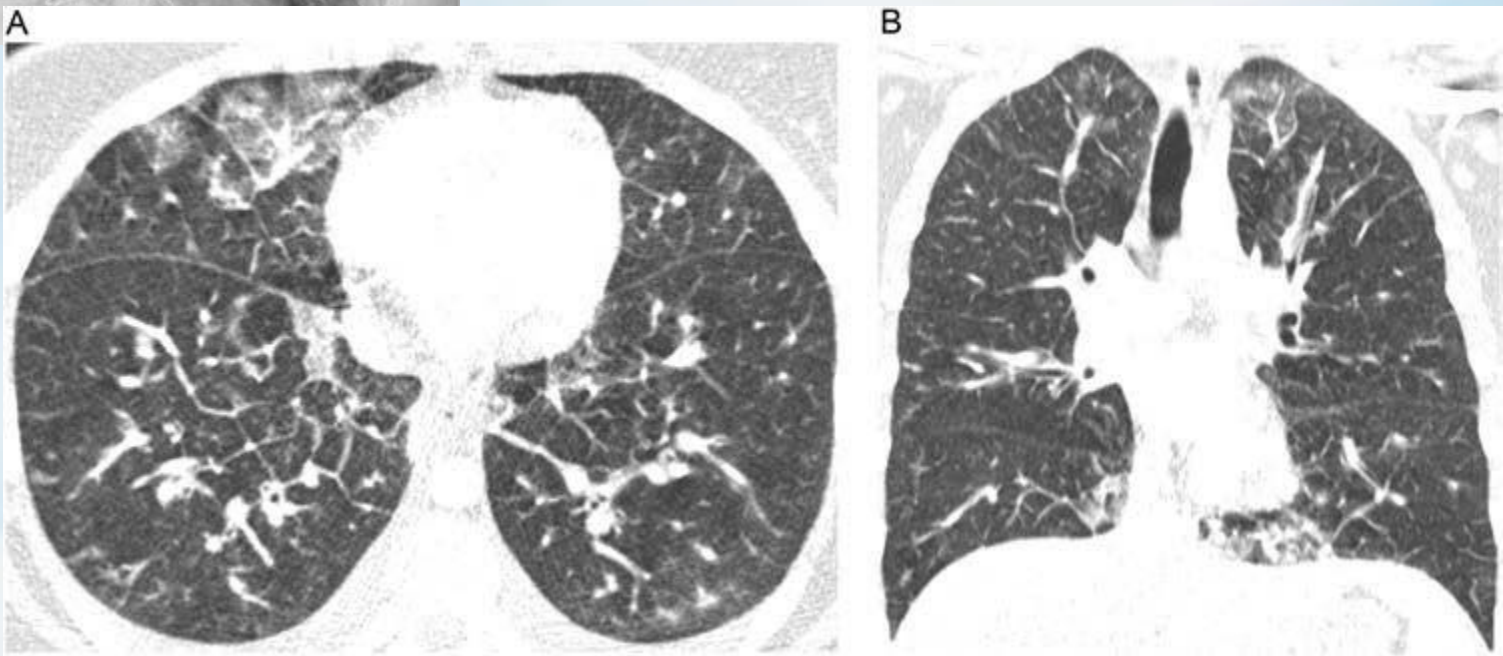

UCSF Fresno

The Spectrum of Inhalation Injury

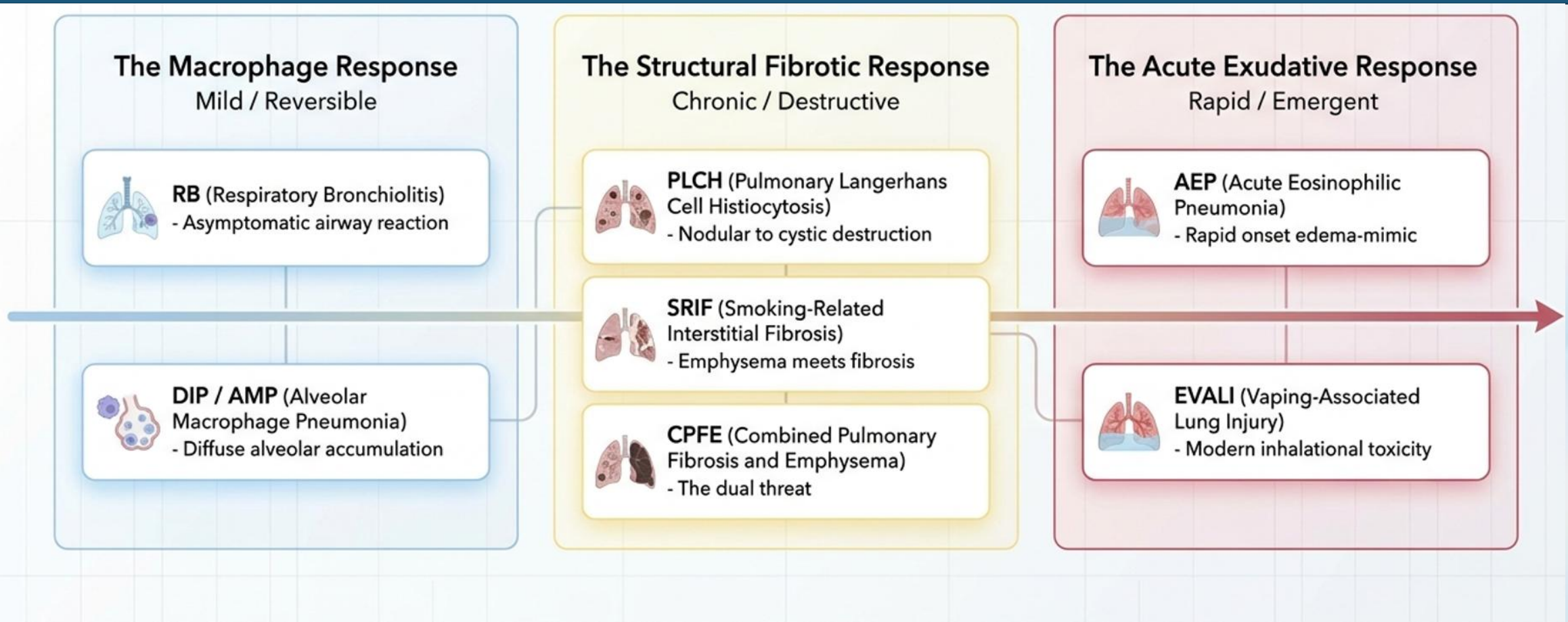

UCSF Fresno

EVALI represents the modern spectrum of acute inhalation toxicity

- Vaping-use associated lung injury within 90 days of use
- Peak incidence in 2019-2020
- Strongly associated with THC(48%) and Nicotine (9%)
- Acute/subacute presentation (dyspnea, CP)

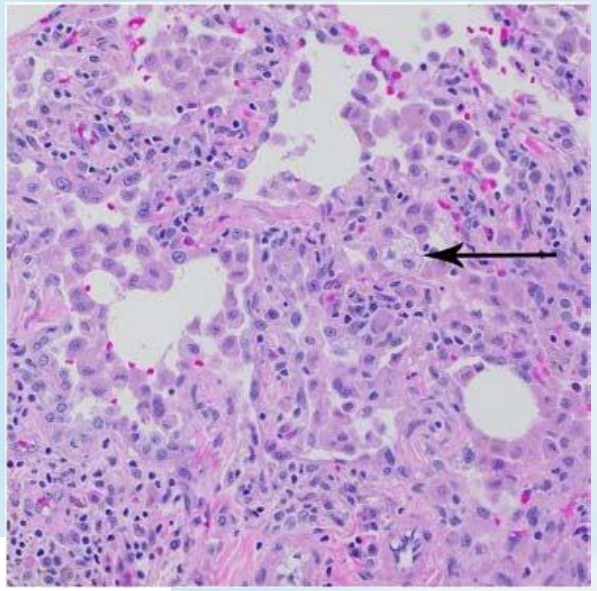

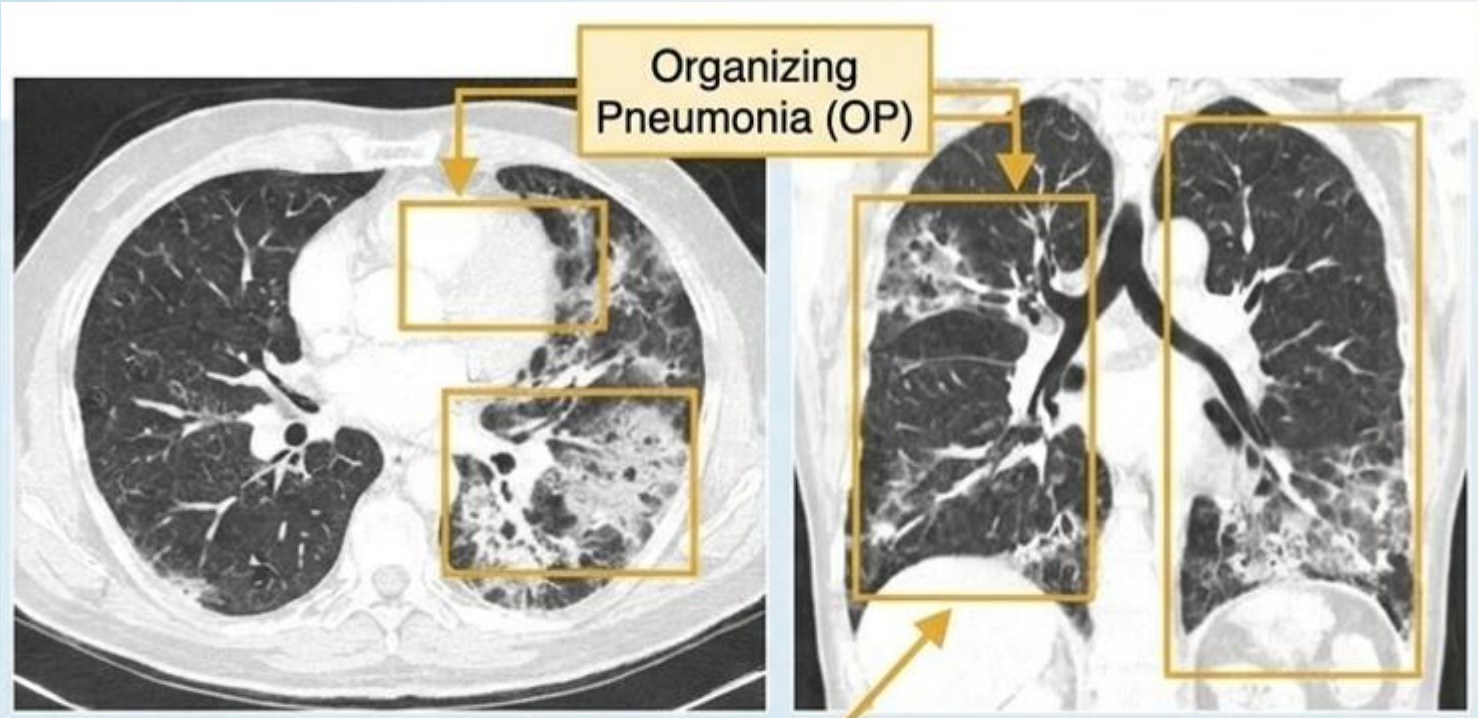

Variable patterns including Organizing Pneumonia (OP) and Diffuse Alveolar Damage (DAD). Note peribronchovascular sparing (seen in 40% of cases).

UCSF Fresno

The SR-ILD Diagnostic Synthesis Matrix

Entity	Dominant CT Pattern	Lung Zone distribution	Key Pathology Hallmark
RB	Centrilobular GG nodules	Upper predominant	Pigmented macrophages in airway
DIP/AMP	Diffuse GG opacities & cysts	Lower predominant	Diffuse intra-alveolar macrophages
PLCH	Nodules → cavitation → cysts	Mid/upper (bases spared)	CD1a+ Langerhans cells, stellae nodules
SRIF	Thick-walled collapsing cysts	Peripheral/ upper	Hyalinized ropey collagen
CPFE	Emphysema +UIP honeycombing	Apical emphysema/ basal Fibrosis	Emphysema +fibroblast foci UIP
AEP	Edema-mimic, septal thickening	Peripheral	>25% BAL eosinophilia
EVALI	OP or DAD pattern	Variable (peribronchovascular sparing)	Foamy macrophages

The Multidisciplinary Imperative

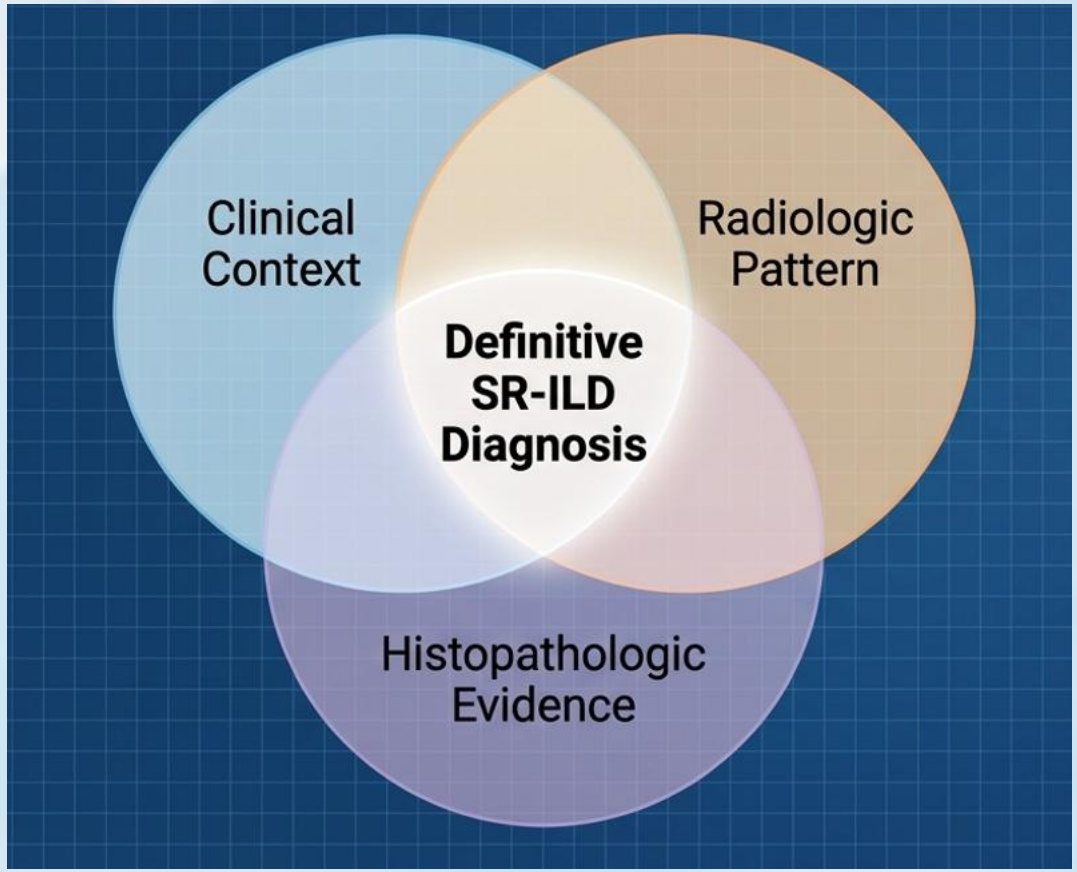

- Imaging findings frequently overlap; precise pattern recognition is critical
- Lack of consensus terminology requires good communication between radiologist and clinicians
- When clinical and CT findings are indeterminate, targeted biopsy and a multidisciplinary ILD board approach prevents misdiagnosis

Take-Home Messages

- Smoking-related ILD is a spectrum of overlapping macrophage, structural fibrotic, and acute exudative responses.
- Distribution and morphology on CT are key discriminators: airway-centered RB, diffuse lower-lung DIP/AMP, upper-lung nodulocystic PLCH, and emphysema-associated fibrosis in SRIF/CPFE.
- AEP and EVALI should be considered when acute respiratory illness follows new or changed inhalational exposure.
- Smoking cessation is central across the spectrum and may stabilize or improve several smoking-related phenotypes.
- When clinical and imaging findings are indeterminate, integrate radiology, pathology, and clinical data through multidisciplinary ILD review.

Thank You for your attention

Questions or Comments are welcome

eyad.almasri@ucsf.edu

UCSF Fresno